

Prolonged Cerebral Salt Wasting Syndrome after Craniotomy Due to Subdural Hematoma and Intracranial Hemorrhage: A Case Report and Literature Review

Parviz Amri¹, Ebrahim Hejazian², Fatemeh Amri^{3*}

¹Department of Anesthesiology, Faculty of Medicine, Babol University of Medical Sciences, Babol, Iran.

²Department of Surgery, Faculty of Medicine, Babol University of Medical Sciences, Babol, Iran.

³Department of Pediatrics, School of Medicine, Tabriz University of Medical Sciences, Tabriz, Iran.

ARTICLE INFO

Article history:

Received 17 June 2025

Revised 08 July 2025

Accepted 22 July 2025

Keywords:

Cerebral salt-wasting syndrome;
Hyponatremia;
Polyuria;
Subdural hematoma;
Intracranial hemorrhage

ABSTRACT

Cerebral salt wasting syndrome (CSWS) is a cause of hyponatremia in patients with brain injury, but it often improves in a short time. In this article, a patient with prolonged CSWS after craniotomy for subdural hematoma (SDH) and intracranial hemorrhage (ICH) is presented. A 73-year-old woman was transferred to the ICU due to a decreased level of consciousness (GCS= 9) with a diagnosis of SDH and ICH. The patient had a history of atrial fibrillation. The pupils were mid-sized and reactive. BP= 130/90 mm/Hg, HR=80/min, T=37.3, and initial tests were HB=12.7 gr/dl, Bun=12, Cr=0.7, Na=138 Meq/lit, K=4meq/lit, Ptt=25 Sec, INR=1.1, ESR=10. The patient was intubated 48 hours later due to a decreased level of consciousness and underwent craniotomy and hematoma drainage. From the 4th day after the operation, the patient developed hyponatremia and polyuria, but despite the administration of hypertonic sodium and normal saline, the hyponatremia persisted. On the 8th day after the operation, fludrocortisone was started, one tablet twice a day, and the patient showed a partial response to the treatment after one week, but the hyponatremia was corrected after 2 weeks. CSWS is more common and prolonged in severe and multiple brain injuries, and in these cases, the administration of fludrocortisone in addition to normal sodium and hypertonic sodium is helpful.

Introduction

Sodium is the main extracellular ion in the body. Its normal level is 140 mEq/L. Sodium less than 135 mEq/L is called hyponatremia. Hyponatremia has various causes. Hyponatremia associated with brain injury is usually caused by SIADH and CSWS. Differentiating these two clinical conditions is of particular importance because of the differences in treatment [1-6].

CSWS is a set of signs and symptoms of polyuria, hyponatremia, and high urinary sodium that is commonly seen after SAH. This syndrome is seen in brain tumors, metastatic carcinoma, neuromeningeal tuberculosis, and stroke, and also after brain trauma and surgery [7-14].

Cases of CSWS after extralumbar drainage of CSF fluid in patients with normal pressure hydrocephalus and also in Alzheimer's patients have been reported [15-16]. Unlike SIADH, where the mechanism of hyponatremia is well-defined, the mechanism of hyponatremia in CSWS is unknown. Possible mechanisms of CSWS include release of BNP from damaged brain tissue or from the

The authors declare no conflicts of interest.

*Corresponding author.

E-mail address: Fatemeamri22@gmail.com

DOI: [10.18502/aacc.v12i3.21320](https://doi.org/10.18502/aacc.v12i3.21320)

Copyright © 2026 Tehran University of Medical Sciences. Published by Tehran University of Medical Sciences.



This work is licensed under a Creative Commons Attribution-NonCommercial 4.0 International license (<https://creativecommons.org/licenses/by-nc/4.0/>). Noncommercial uses of the work are permitted, provided the original work is properly cited.

atria and excretion of sodium along with water from the kidneys. Another mechanism is a decrease in sympathetic system activity, followed by a decrease in renin-angiotensin-aldosterone axis activity and increased excretion of sodium and water [4, 7].

Hyponatremia in CSWS usually occurs acutely and with greater speed and severity than in SIADH [2]. Inappropriate treatment of CSWS and failure to differentiate it from SIADH and volume restriction causes hyponatremia, seizures, severe hypovolemia, and sometimes shock [11, 17]. CSWS is associated with hyponatremia, sodium <135, and high urine sodium, usually >40, urine osmolality >100 mosmol/kg, and signs and symptoms of hypovolemia such as decreased skin turgor, hypotension, decreased intracranial pressure, and high hematocrit [4]. SIADH is also associated with hyponatremia and high urine sodium but is usually associated with hypervolemia and low urine output [4]. The treatment of CSWS is the administration of sodium-containing fluids, hypertonic sodium, and sometimes fludrocortisone, but the treatment of SIADH is fluid restriction, furosemide, and, in the case of severe hyponatremia, hypertonic sodium [4, 18]. In this article, we present a 72-year-old female patient with prolonged CSWS after craniotomy for subdural hematoma and ICH who responded to fludrocortisone, and then a brief review of the relevant literature is performed.

Case Report

A 73-year-old woman was transferred to the ICU due to a decreased level of consciousness with a diagnosis of ICH. The patient had a history of mild heart failure (EF = 45%) with atrial fibrillation, which was treated with metoprolol and rivaroxaban. A cerebral CT scan and SDH showed left frontoparietal ICH and mediolateral shift =13 mm. There was hemiparesis and hemiplegia on the right side. GCS=9. Pupils were mid-sized and reactive (Figure 1). Vital signs and initial tests include (Table 1):

BP= 130/90 mm/Hg, HR=80/min, T=37.3, HB=12.7 gr/dl, Bun=12, Cr=0.7, Na=138 Meq/lit, K=4meq/lit, Ptt=25 Sec, INR=1.1, ESR=10

The patient was intubated 48 hours later due to a further decreased level of consciousness and underwent craniotomy and hematoma drainage. After the operation, he was connected to a ventilator in ACMV (assist-controlled mandatory ventilation) mode. A midazolam and fentanyl infusion was started.

The pupils were reactive, but the patient still had right hemiplegia. The arterial blood gas analysis before and after the operation is shown in Table 2. Pentazole 40 mg intravenously twice a day was prescribed to prevent stress ulcers. metoprolol 50 mg daily and losartan 25 mg twice a day were continued.

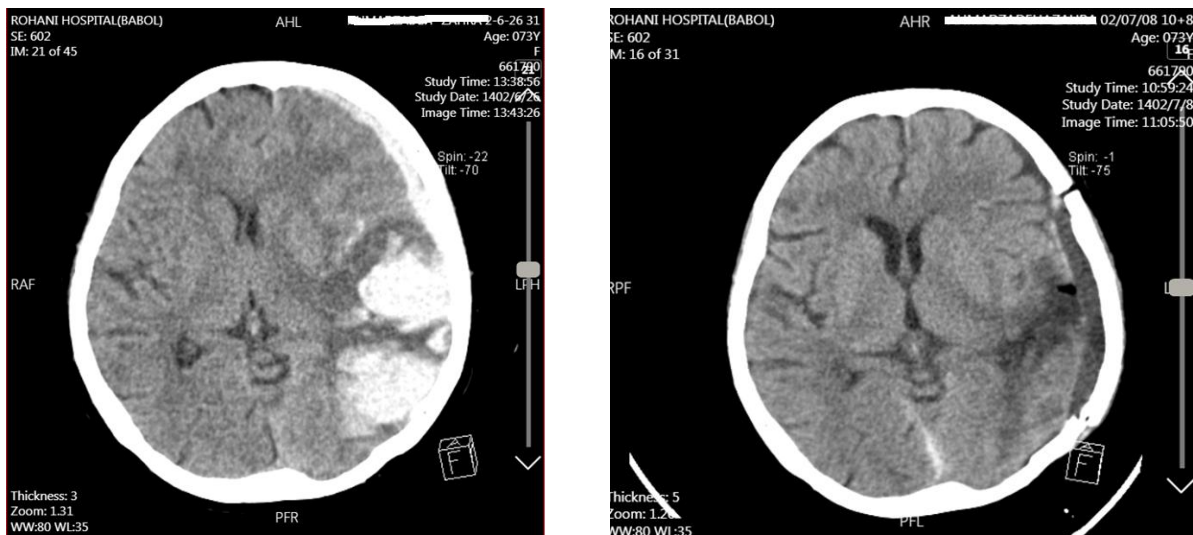


Figure 1- Left side of the brain CT scan and SDH shows left frontoparietal ICH and a 13mm mediolateral shift (MLS), and the right side shows day 10 after surgery.

Table 1- Patient's level of consciousness, blood pressure and Na, K during hospitalization

	Basic	4th day after surgery	5th	7th	10th	14th	22th	27 th
GCS	9	12	12	12	12	12	13	13
SBP/DBP	130/80	130/90	130/90	126/86	125/85	125/85	125/85	130/88
Na	138	133	130	130	128	130	133	137
K	4	4	3.8	3.5	3.3	3.7	3.9	3.5
Intake	4500	4100	4400	4050	4100	3600	4500	3000
Output	6400	6700	4700	7500	4600	5700	5100	3200

Table 2-Arterial blood gas analysis before and after craniotomy surgery

Arterial blood gas analysis parameters	Preoperation	After surgery
PH	7.35	7.57
PaCo ₂ (mm/Hg)	43	26
PaO ₂ (mm/Hg)	110	132
HCO ₃ (mm/Hg)	23	27

Food gavage started at 30 cc every 3 hours and gradually increased to 250 cc every 3 hours. KCL 15% 10 cc per liter of intravenous fluid and MgSO₄ 50% 4 ml daily were prescribed. Intravenous fluids after surgery started at 2.5 liters of normal saline daily and decreased to 1 to 1.5 liters daily with increasing gavage. Blood sugar was measured every 6 to 12 hours with a glucometer and corrected if blood sugar was higher than 200 mg/dl. On the fourth day after surgery, despite the administration of normal saline, the patient developed hyponatremia (Na=133 meq/lit). Intake=4100 ml and Urine Output=6700 ml. The random urine sodium level was 200 mmol/L. Normal saline (3 liters) and hypertonic sodium (5%) (3 vials daily) were started for the patient. However, despite the treatment, the patient's sodium level became 128 mEq/L. On the 12th day after the operation, fludrocortisone, one tablet every 8 hours, was added to the previous treatments. 48 hours later, the patient's sodium gradually reached 130 mEq/L. With daily sodium control, the hypertonic sodium level was adjusted until it was gradually discontinued. On the 30th day of hospitalization, the patient was discharged with a sodium level of 137.

Discussion

In this article, we present a patient with prolonged CSWS after craniotomy for subdural hematoma and ICH who responded to treatment with normal saline and hypertonic sodium with fludrocortisone. The patient initially had normal sodium and developed hyponatremia on the 4th day after surgery. The main cause of the patient's hyponatremia was CSWS, but despite the administration of normal saline and 4 vials of hypertonic sodium daily, the patient remained hyponatremic and responded partially to the addition of fludrocortisone.

Wijaya et al. reported a 56-year-old man with a history of diabetes and hypertension who developed intracerebral hemorrhage (ICH). He underwent ventriculoperitoneal (VP) shunt surgery for hydrocephalus. He developed hyponatremia with increased urinary sodium levels and hypovolemia after the procedure. The patient was treated with normal saline and hypertonic sodium and desmopressin. After treatment, the hyponatremia was corrected. They diagnosed the patient with CSWS. They concluded that CSWS is an important cause of hyponatremia in neurosurgical patients. Prompt diagnosis of CSWS and appropriate treatment with high-

sodium fluids and possibly desmopressin can improve the patient's condition [19].

Our patient also had hyponatremia with high urinary sodium, which responded to treatment with normal saline and hypertonic sodium, but the hyponatremia persisted for a long time, and we prescribed fludrocortisone to achieve a more appropriate response. The main difference between the patient reported by Wijaya et al. and our patient was the desmopressin treatment. Desmopressin probably reduces the amount of water and salt excretion by reducing polyuria.

Oruckaptan et al. reported 2 cases of primary neuroectoderm tumor with intraventricular spread in patients who developed prolonged CSWS [1]. They considered it very important to differentiate this syndrome from SIADH because inappropriate treatment will cause dangerous complications [1]. Of course, our patient had some degree of heart failure, which itself causes hyponatremia, but given that the patient's heart failure was controlled and treated and the patient's sodium was in the normal range before surgery, the patient's postoperative hyponatremia was not related to heart failure.

Wisadianta et al. reported a 66-year-old woman who developed severe hyponatremia after head trauma and was treated at Udayana University Hospital. [2] They diagnosed CSWS after examining the clinical and laboratory signs and treated the patient with normal saline and hypertonic sodium. They stated that hyponatremia caused by CSWS usually occurs acutely with brain damage and that the decrease in extracellular volume in this syndrome is due to impaired sodium transport in the kidneys of patients despite normal kidneys, but the main mechanism of this condition is still not well understood [2]. Ugwendum et al. introduced a patient with lung adenocarcinoma with brain metastasis who developed CSWS [7]. Based on a review of various articles, they proposed two possible hypotheses to explain the loss of serum sodium in this condition. The first hypothesis is the activation of the sympathetic system, which leads to a decrease in renin and aldosterone and ultimately causes the loss of serum sodium and water. The second hypothesis is the increase in brain and atrial natriuretic peptides after brain cell damage, which causes the excretion of water and sodium by the kidneys [7]. CSWS should always be considered as a cause of hyponatremia after brain injury following trauma or craniotomy and should be differentiated from syndrome of inappropriate

antidiuretic hormone (SIADH), because its treatment, although both cause hyponatremia and are sometimes similar, poses risks to the patient if not treated appropriately [7].

Yoo et al. reported a patient who underwent external lumbar drainage (ELD) after ischemic stroke due to hydrocephalus with normal intracranial pressure. After the procedure, the patient developed CSWS. They stated that although SIADH and CSWS have similar clinical manifestations, the pathophysiology and treatment of these two conditions are completely different and that inappropriate treatment can cause seizures and even death, and concluded that CSF drainage shunt placement could be a rare cause of CSWS [16]. Bouchlarhem et al. reported a patient who developed CSWS after subarachnoid hemorrhage (SAH). They stated that the diagnosis of CSWS is not simple, and it is difficult to differentiate it from SIADH because both occur after brain injury and cause hyponatremia [17]. The main difference between the patient reported by Bouchlarhem et al. and our patient was the development of severe hypovolemia and subsequent hypotension, but in our patient, despite prolonged hyponatremia due to repeated administration of normal saline, this condition was less observed.

Wu et al. reported a patient with Down syndrome who developed CSWS due to pituitary apoplexy. The patient's initial symptoms were severe headache, thirst, and polyuria. Laboratory results included hyponatremia, decreased plasma osmolality, and increased urine osmolality. Initially, the patient was given fluid restriction, but the patient's condition worsened, and then treatment with normal saline was started, and serum sodium and chloride levels gradually normalized. They finally proposed the diagnosis of CSWS associated with pituitary apoplexy for the patient [20].

In our patient, it seems that the main reason for the persistence of hyponatremia despite the administration of normal saline and hypertonic Na was continuation of brain damage and the simultaneous presence of two injuries: subdural hematoma and severe ICH in the brain. Therefore, in cases of prolonged CSWS, maintaining the sodium level at the lower limit of normal and adding flucortisone will correct the CSWS.

Conclusion

CSWS is more common and prolonged in severe and multiple brain injuries, and the administration of fludrocortisol in addition to normal sodium and hypertonic sodium is helpful.

Abbreviations

CSWS: cerebral salt wasting syndrome

SDH: subdural hematoma

ICH: intracranial hemorrhage

GCS: Glasgow Coma Scale

SAH: Subarachnoid Hemorrhage

SIADH: Syndrome of inappropriate antidiuretic hormone secretion

MLS: Mediolateral Shift

ACMV: Assist controlled mandatory ventilation

Acknowledgment

We would like to thank the staff and head nurse of the intensive care unit of Ayatollah Rouhani Hospital for their care of the patient.

References

- [1] Oruckaptan HH, Ozisik P, Akalan N. Prolonged cerebral salt wasting syndrome associated with the intraventricular dissemination of brain tumors: report of two cases and review of the literature. *Pediatr Neurosurg.* 2000; 33(1):16-20.
- [2] Wisadanta R, Riani NW. Cerebral salt wasting syndrome: A case report. *Intisari Sains Medis.* 2023; 14(1):320-3.
- [3] Al-Helal B, Abdallah E, Yousef A, Asad R, Reda M. Renal salt wasting syndrome in a patient with COVID-19; a case report and review of the literature. *J Renal Endocrinol.* 2020; 7(1):e02-.
- [4] Tenny S, Thorell W. Cerebral salt wasting syndrome. In: *StatPearls [Internet]* 2023. StatPearls Publishing.
- [5] Kawahara T, Toda M, Kanagawa M, Toyama N, Kawahara C, Inazu T. Etiology and Clinical Features of Patients With Hyponatremia in the Emergency Department: A Cross-sectional Study. *J Clin Endocrinol Metab.* 2025:dgaf192.
- [6] Gilbert SJ. Sodium and Water Disorders. *Advances in Kidney Disease and Health.* 2025; 32(1):41-9.
- [7] Ugwendum D, Onana AE, Gutlapalli SD, Okorie II, Ullah AA, Tahir MK, et al. Cerebral Salt Wasting Syndrome Following Right Occipital Craniotomy in a Patient With Metastatic Lung Adenocarcinoma. *Cureus.* 2023;15(7).
- [8] Memon W, Akram A, Popli K, Spriggs JB, Rehman S, Gipson G, et al. Cerebral Salt-Wasting Syndrome in a Patient With Active Pulmonary Tuberculosis. *Cureus.* 2022; 14(1).
- [9] Baracan A, Baracan AM, Moldovan M. Cerebral Salt-Wasting Syndrome in Severe Brain Trauma: A Case Report and Review of the Literature. *Cureus.* 2025;17(3).
- [10] Rojas-Urrea A, Arias-Mariño D, García-Agudelo L, Gonzalez-Calderon IC. Cerebral salt wasting syndrome in a patient who suffered a gunshot traumatic head injury: a case report. *Folia Medica.* 2025;67(1):e130280.
- [11] Rossi A, Corbelli L, Soldovieri S, Barbato A, Cerutti M, Pontone M, et al. Challenging management of

- electrolyte imbalances in neurosurgical patient: cerebral salt wasting case report. *Endocr Abstr.* 2025; 110. Bioscientifica.
- [12] Tran V, Flores J, Sheldon M, Pena C, Nugent K. Fluid and Electrolyte Disorders in Traumatic Brain Injury: Clinical Implications and Management Strategies. *J Clin Med.* 2025; 14(3):756.
- [13] Hasan S, Uff C. Neuroendocrine dysfunction following traumatic brain injury: current insights and emerging perspectives. *Best Pract Res Clin Endocrinol Metab.* 2025;102006.
- [14] Qian A, Zheng L, Duan J, Li L, Xing W, Tang S. Hyponatremia is associated with malignant brain edema after mechanical thrombectomy in acute ischemic stroke. *BMC neurology.* 2025; 25(1):41.
- [15] Maesaka JK, Imbriano LJ, Grant C, Miyawaki N, Muralidharan R. Haptoglobin-related protein without signal peptide induces high prevalence of renal salt wasting and new syndrome of salt wasting in Alzheimer's disease. *Med Res Arch.* 2025;13(1).
- [16] Yoo JH, Park KD, Lim OK, Lee JK. Cerebral salt wasting syndrome caused by external lumbar drainage in a patient with chronic hydrocephalus. *Ann Clin Neurophysiol.* 2022; 24(1):30-4.
- [17] Bouchlarhem A, Haddar L, Berrichi H, Jabri M, Lachhab A, El houda Lamassab N, et al. Cerebral Salt Wasting Syndrome (CSW): An unusual cause of hypovolemia after spontaneous cerebral hemorrhage successfully treated with fludrocortisone. *Radiol Case Rep.* 2022;17(1):106-10.
- [18] Elledge SR, Shewmaker JW, Yang S, Blunck JR. Fludrocortisone evaluation in aneurysmal subarachnoid hemorrhage patients with cerebral salt wasting (Flush Salt). *Clin Neurol Neurosurg.* 2023; 225:107568.
- [19] Wijaya WN, Anggraeni N, Valentino A. Hyponatremia After Intracranial Hemorrhage: Cerebral Salt Wasting Syndrome (CSWS) or The Syndrome of Inappropriate Antidiuretic Hormone Secretion (SIADH)?. *Bioscientia Med.* 2025;9(1):6058-72.
- [20] Wu J, Yan Z, Li B, Yu X, Huang H. Pituitary Apoplexy-associated Cerebral Salt Wasting Syndrome: A Case Report and Literature Review. *Clin Ther.* 2023;45(12):1293-6.