

Management of Bronchial Hydatid Cyst with Endobronchial Intubation along with Patient Positioning and Bougie: A New Approach

Debendra Kumar Tripathy¹, Sameer Sharma¹, Mohammed Shafiq Shajahan^{1*}, Madhur Uniyal²

¹Department of Anesthesiology, All India Institute of Medical Sciences, Rishikesh, India.

²Department of Trauma Surgery and Critical Care, All India Institute of Medical Sciences, Rishikesh, India.

ARTICLE INFO

Article history:

Received 16 January 2021

Revised 09 February 2021

Accepted 23 February 2021

Ideally, bronchial hydatid cyst disease requires lung isolation as well as lung separation during anaesthesia. Patients undergoing thoracotomy for bronchial hydatid cyst require isolation of healthy lung for protection against transbronchial spread of hydatid fluid [1]. We propose an alternative approach to double lumen tube (DLT) and Univent tube for mechanical ventilation and isolation with an endobronchial endotracheal tube (ETT) with a combination of patient positioning and gum elastic bougie to provide a suction route for the operated lung.

A 12-year-old patient diagnosed with symptomatic pulmonary hydatid cyst with complaints of persistent productive cough for two months and worsening breathlessness of one week duration was posted for right-sided thoracotomy. DLT is preferred during thoracotomy for hydatid cystectomy to control ventilation and prevent flooding of the healthy lung [2-4]. However, we had a narrow time frame for getting the surgery conducted due to worsening patient status and remote location of the patient with a probability of non-compliance. During this time frame, the necessary paediatric airway equipment (DLT and Univent) was not available. However, due to urgent nature of the surgery, we had to go ahead with the available resources. We could not use DLT as the smaller size required was not available. Bronchial intubation with

ETT may not achieve collapse of the operative lung and may even fail to prevent transbronchial spread as the operative lung cannot be suctioned with this technique [1, 5-7]. Therefore, after inducing anesthesia with standard ASA monitoring, we passed a 5.5 mm ID cuffed ETT and was secured in the trachea under direct laryngoscopy. An arterial line and a central line was secured after induction. Using a fiberoptic bronchoscope, the single lumen ETT was advanced into the left main bronchus to achieve one lung ventilation. The patient was ventilated with pressure control mode. Inspiratory pressures were adjusted to deliver a tidal volume of 4-5 ml/kg. Respiratory rate was titrated according to ETCO₂. PEEP was titrated to maintain the saturation of more than 94% and anaesthesia was maintained with Sevoflurane and air. Noradrenaline infusion was adjusted to provide minimal support and avoid changes in the haemodynamics caused by intra thoracic manipulation by the surgeon. Surgeon had informed us regarding inadvertent rupture and suspected spillage in the tracheobronchial tree.

After the completion of surgery which had taken four hours to complete, the ventilated lung was found to be contamination free under fiberoptic bronchoscopic visualisation. However, above the level of cuff near the carina, contaminant spillage could be seen through the transparent ETT. The patient was put in Trendelenburg

The authors declare no conflicts of interest.

*Corresponding author.

E-mail address: shafinmbb@gmail.com

position for 15 minutes to allow drainage of the fluid. Bronchoscopy showed reduction of the spillage fluid. Passing the fiberoptic bronchoscope along with ETT could have been the best method to ensure suction of operated lung and carina under vision [8] but due to narrow passage the glottis opening could not accommodate the bronchoscope along with ETT. Passing a soft suction catheter was not possible as it is not firm enough. Therefore, under direct laryngoscopy, a hollowed gum elastic bougie was passed along the ETT into the trachea. Continuous suction was connected to the bougie and suction of operated lung as well as trachea was achieved and was confirmed with fiberoptic bronchoscope passed through the ETT. After confirmation of no residual spillage at carina and trachea, the ETT was repositioned to endotracheal position under fiberoptic bronchoscopic guidance and the bougie kept in

situ was seen in the right main bronchus with continuous suction. Patient was extubated and postoperative course was uneventful with epidural analgesia. Patient was followed up in ward with serial chest x-rays. The patient was mobilised on the 2nd postoperative (PO) day and discharged on the 5th PO day.

Our technique of using a combination of Trendelenburg position to provide drainage and gum elastic bougie to provide continuous suction with endobronchial intubation of endotracheal tube can be a good alternative in absence of DLT or Univent. In the absence of Univent tube and bronchial blockers, this technique gives a good alternative to prevent spread of spillage. If faced with a similar situation without an alternative available, this technique may be used again owing to its effectiveness as it resulted in a positive outcome and early discharge of the patient.

Figure 1- A: Contaminant spillage above the cuff of ETT. B: Gum elastic bougie in place for suctioning C: Passage of gum elastic bougie to suction the contaminants D: Repositioning of ETT after confirmation of no residual spillage.

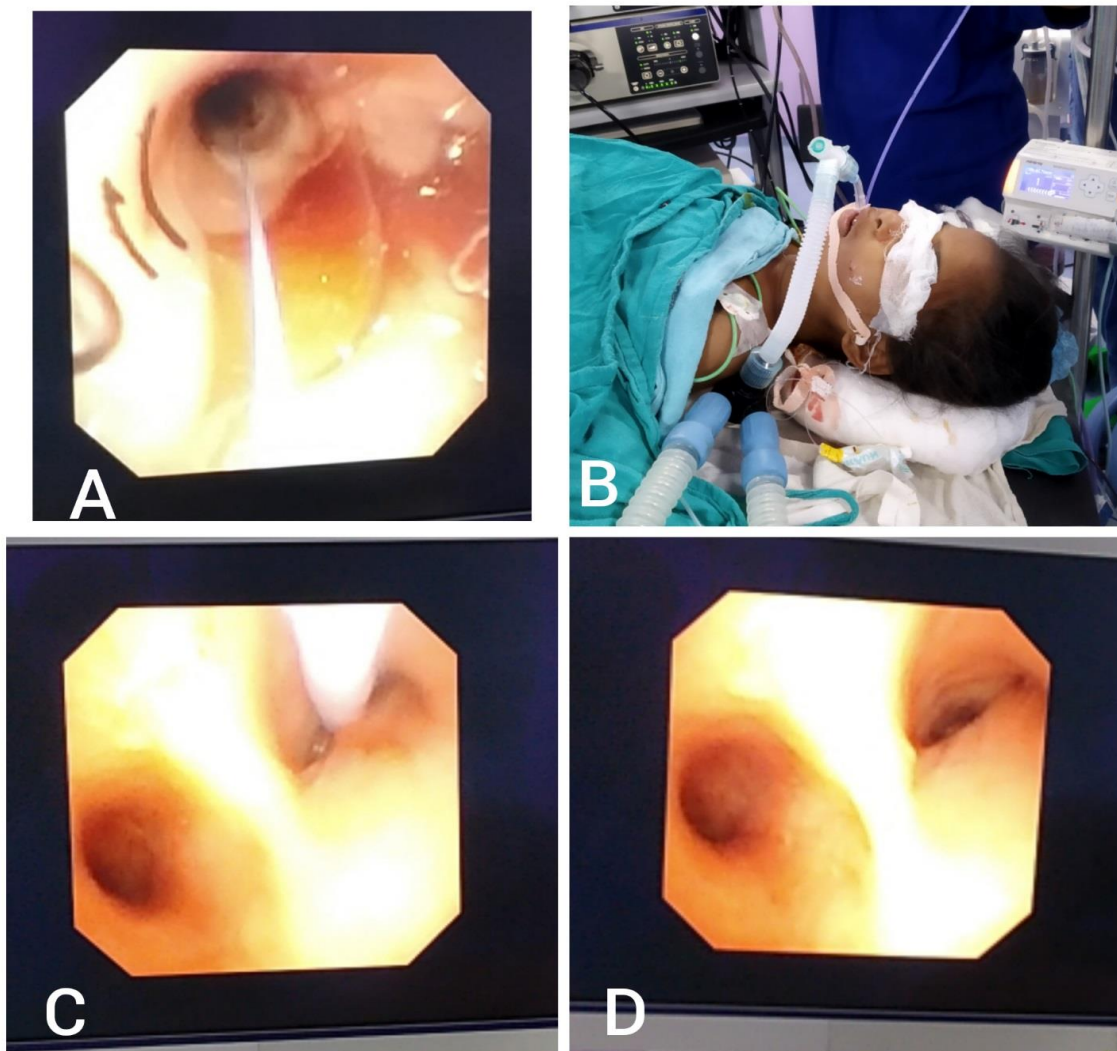
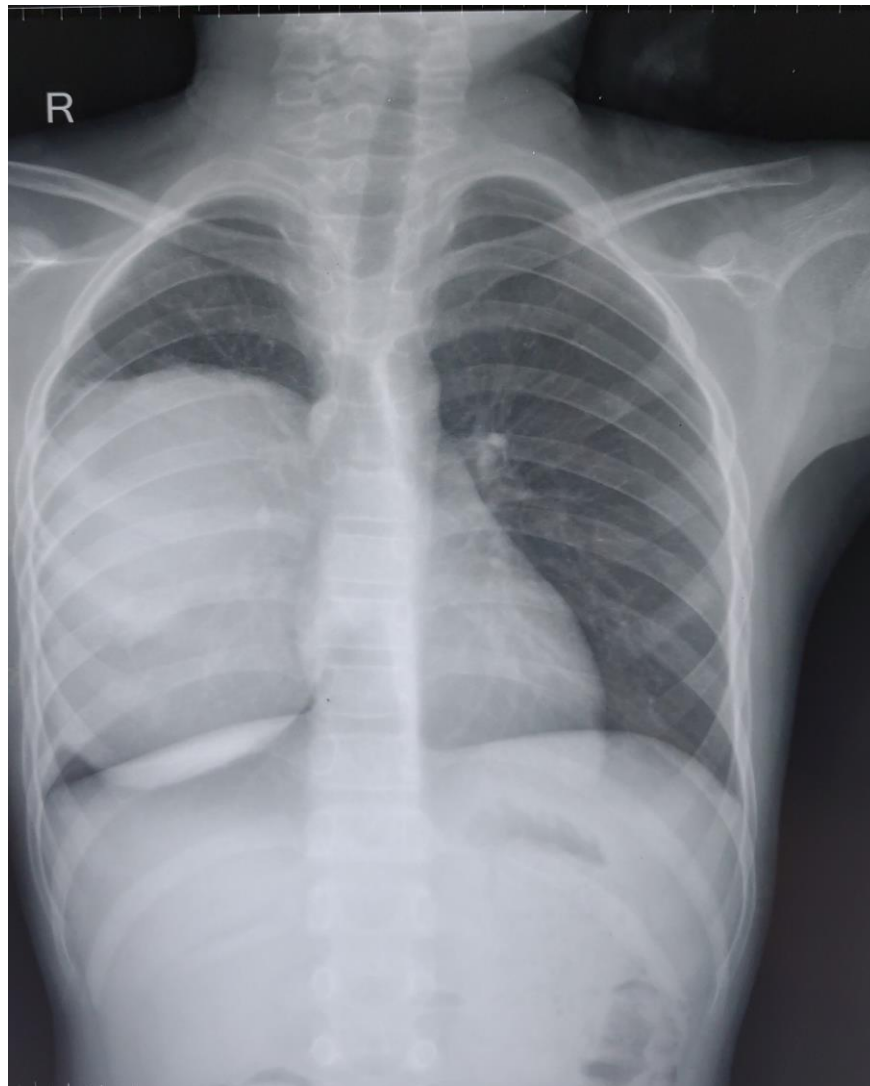


Figure 2- Chest radiograph showing pulmonary hydatid cyst in the right lung

References

- [1] Singh H, Kohli H, Grewal A, Budhiraja S. Anesthetic considerations in a child with bilateral hydatid cysts of lung. *Indian J Anaesth.* 2008; 52:849
- [2] Anthi A, Katsenos C, Georgopoulous S, Mandragos K. Massive rupture of hydatid cyst associated with mechanical ventilation. *Anesth Analg.* 2004; 98(3):796-7.
- [3] Bickel A, Loberant N, Singer-Jordan J, Goldfeld M, Daud G, Eitan A. The laparoscopic approach to abdominal hydatid cysts A prospective nonselective study using the isolated hypobaric technique. *Arch Surg.* 2001; 136(7):789-95.
- [4] Smego RA, Jr, Sebanego P. Treatment options for hepatic cystic echinococcosis. *Int J Infect Dis.* 2005; 9(2):69-76.
- [5] Fabila TS, Menghraj SJ. One lung ventilation strategies for infants and children undergoing video assisted thoracoscopic surgery. *Indian J Anaesth.* 2013; 57(4):339-44.
- [6] Baraka A, Dajani A, Maktabi M. Selective contralateral bronchial intubation in children with pneumothorax or bronchopleural fistula. *Br J Anaesth.* 1983; 55(9):901-4.
- [7] Rowe R, Andropoulos D, Heard M, Johnson K, DeCampi W, Idowu O. Anesthetic Management of patients undergoing thoracoscopy. *J Cardiothorac Vasc Anesth.* 1994; 8:563-6.
- [8] Nozaki H, Okuaki A. A newly designed flexible fiberoptic bronchoscope for use in intensive care units. *Intensive Care Med.* 1979; 5:199-202.