

Barotrauma in COVID-19 Patients

Farahnaz Fallahian^{1*}, Atabak Najafi², Arezoo Ahmadi²

¹Sina Hospital, Tehran University of Medical Sciences, Tehran, Iran.

²Department of Anesthesiology and Critical Care, Sina Hospital, Tehran University of Medical Sciences, Tehran, Iran.

ARTICLE INFO

Article history:

Received 31 August 2021

Revised 21 September 2021

Accepted 05 October 2021

Keywords:

COVID-19;

Acute respiratory distress syndrome;

Pulmonary barotrauma

ABSTRACT

Clinical manifestations of COVID 19 is still unknown. We performed this study to determine the occurrence of pulmonary barotrauma as a complication of this disease.

In this retrospective study, a total of 955 COVID 19 patients with respiratory insufficiency requiring oxygen support or invasive ventilation admitted to ICU of Sina Hospital from 20 March 2020 to 9 June 2021, were included and their chest imaging reviewed. Here, we report results of chest imaging of first 92 patients of this group.

Barotrauma (pneumothorax, pneumomediastinum, pneumopericardium) occurred in 11 (11.9%) of 92 patients with coronavirus disease 2019 (COVID-19) infection requiring ICU admission for respiratory support and monitoring.

It seems barotrauma is a common complication of COVID 19 disease. The role of increased respiratory efforts, patient or ventilation induced lung injury, viral and host response should be assessed. It needs to consider the occurrence of barotrauma in Patients with COVID-19, before expansion of dead space for treatment and limiting the ventilation effects.

Coronavirus is an enveloped, positive single-strand RNA virus. It belongs to the Orthocoronavirinae subfamily, as the name suggests, whose members show characteristic “crown-like” spikes on their surfaces [1].

In this retrospective study, a total of 955 COVID 19 patients with respiratory insufficiency requiring oxygen support or invasive ventilation admitted to ICU of Sina Hospital from 20 March 2020 to 9 June 2021, included and their chest imaging reviewed. Here, we report results of chest imaging of first 92 patients of this group.

Barotrauma included of pneumothorax, pneumomediastinum, pneumopericardium, and subcutaneous emphysema.

Chest x-rays and imaging suspected barotrauma were reviewed by intensivists and radiology professors.

In this study, if the patient had occult pneumothorax and was unstable to perform chest CT scan, or

insufficient view for detection of pneumomediastinum by portable chest X ray, all were short comings of the study.

Statistical Analysis

Quantitative and qualitative data are reported as median and number (percentage).

Results

Barotrauma (pneumothorax, pneumomediastinum, pneumopericardium) occurred in 11 (11.9%) of 92 patients with coronavirus disease 2019 (COVID-19) infection requiring ICU admission for respiratory support and monitoring.

Pictures 1 to 7, shows examples of imaging of barotrauma in our patients:

The authors declare no conflicts of interest.

*Corresponding author.

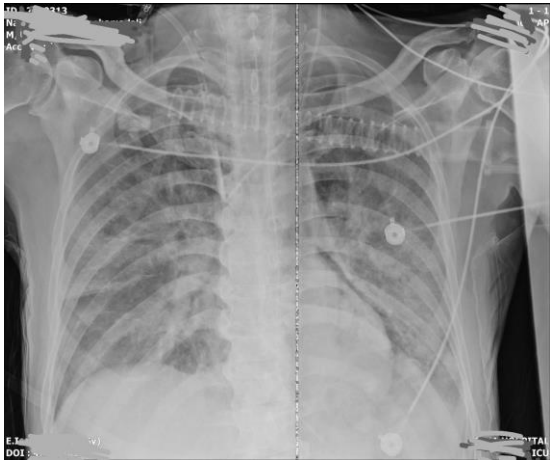E-mail address: falahianfff@yahoo.com

Copyright © 2022 Tehran University of Medical Sciences. Published by Tehran University of Medical Sciences.

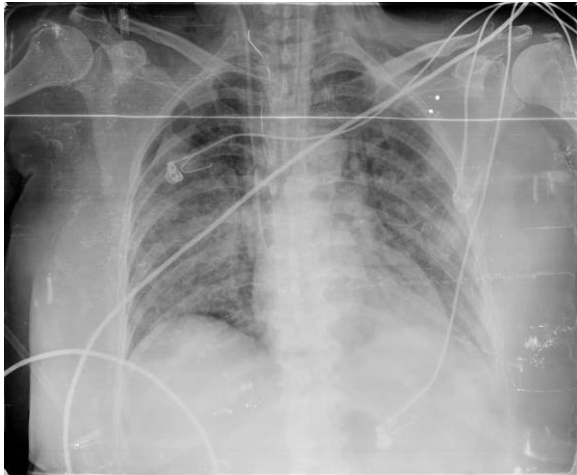

This work is licensed under a Creative Commons Attribution-NonCommercial 4.0 International license (<https://creativecommons.org/licenses/by-nc/4.0/>). Noncommercial uses of the work are permitted, provided the original work is properly cited.

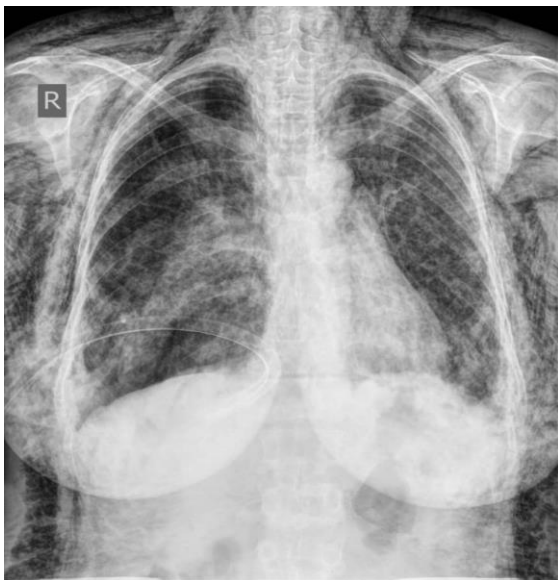Picture 1- Pneumothorax and pneumopericardium



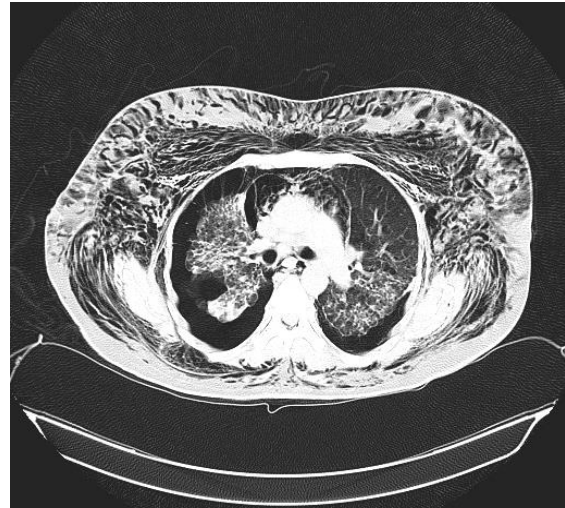Picture 2- Pneumothorax



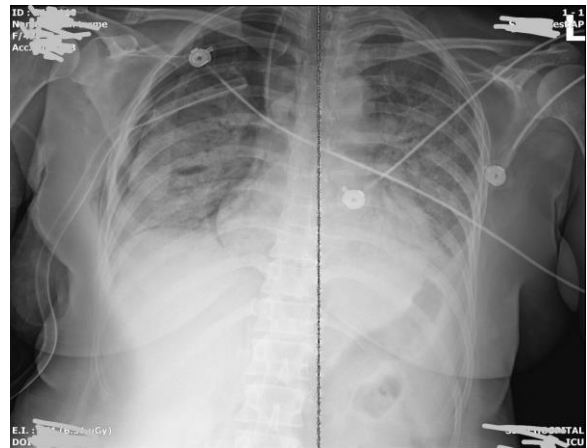
Picture 3- Pneumothorax and extensive subcutaneous emphysema



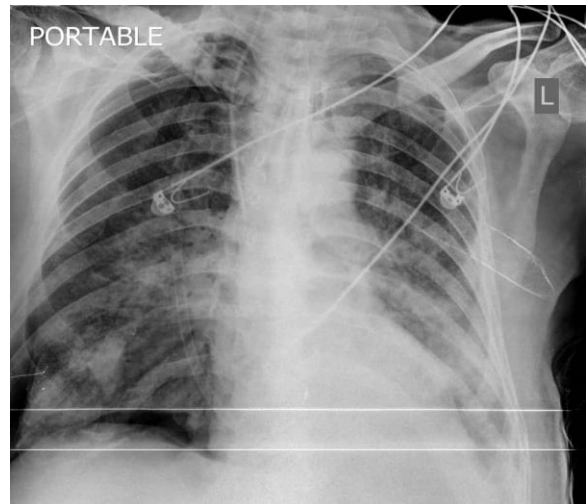
Picture 4- Bilateral pneumothorax, Pneumomediastinum, Extensive subcutaneous emphysema



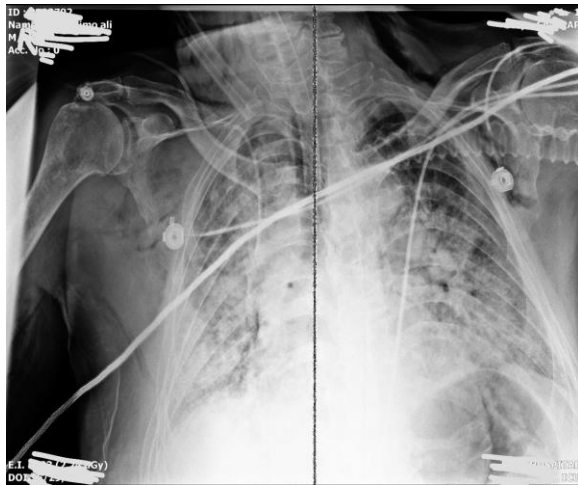
Picture 5- Pneumothorax, Pneumomediastinum, Pneumopericardium



Picture 6- Pneumothorax



Picture 7- Pneumothorax, Pneumomediastinum, Subcutaneous emphysema



Discussion

In a study [2], of 601 patients with COVID-19 infection who underwent invasive mechanical ventilation, there were 89 (15%) patients with one or more barotrauma events for a total of 145 barotrauma events (24% overall events) (95% confidence interval [CI]: 21%, 28%).

Of 285 patients with acute respiratory distress syndrome on invasive mechanical ventilation during the previous 4 years, 28 patients (10%) had 31 barotrauma events, with an overall barotrauma rate of 11% (95% CI: 8%, 15%; $P < .001$ vs the group with COVID-19 infection) [2]. Barotrauma is an independent risk factor for death in COVID-19 and is associated with a longer hospital stay. Patients with coronavirus disease 2019 (COVID-19) infection and invasive mechanical ventilation had a higher rate of barotrauma than patients with acute respiratory distress syndrome and patients without COVID-19 infection [2].

It is likely that the assessment of the intensity of the inspiratory efforts—particularly in the early phase of the disease—is a first step toward clarifying the degree to which ventilation-induced lung injury plays a role in disease progression [3]. Indeed, injury may be due either to the natural evolution of COVID-19—a consequence of the interaction between the viral load and the host response—or to the adverse effects of spontaneous breathing and/or inappropriate mechanical ventilation (3). If further data confirm their findings, the ventilatory treatment should be modified accordingly to limit disease progression and duration. In this new disease, the “evidence” is not immediately available, but it is built by a number of contributions. The results of this paper [3] suggest that excessive respiratory drive may be relevant in COVID-19.

positive pressure ventilation (PPV) in patients with increased intrathoracic pressure (injured, stiff lungs or

chest wall) or intra-abdominal pressure (morbid obesity, abdominal compartment syndrome) may act to decrease renal blood flow by increasing renal venous pressure (which diminishes renal perfusion pressure) and by compressing the renal vasculature leading to AKI [4-7].

In a study (8), of Ninety-one COVID-19 patients who admitted to ICU, 64 (70.3%) required mechanical ventilation. Among the ventilated patients, 20 (31.2%) developed stage 3 AKI during the ICU stay. Compared with non-AKI patients, patients with AKI were most likely to be men (88.2% vs 40.9%; OR = 10.8; 95%CI, 2.5-46.7; $P < 0.01$) and showed higher BMI (32.0 [6.7] vs 27.8 [6.8]; $P = .03$).

At the time of AKI development, all 17 (100%) included patients who developed AKI exhibited IAH with a median IAP of 23 (8) cm H₂O. Eleven (64.7%) had severe IAH and tended to show higher rates of both RRT requirement (54.6% vs 16.7%; OR = 6.0; 95%CI: 0.7-50.6; $P = .13$) and in-ICU mortality (72.7% vs 50%; OR= 2.7; 95%CI, 0.4-18.5; $P = .35$) compared with patients with non-severe IAH (8). At the time of AKI development, all included patients showed relatively preserved pulmonary compliance (44 [10] mL/cm H₂O) and were treated with high PEEP levels (12 [4] cm H₂O) and highly positive 24-hour fluid balance (2,070 [1,975] mL), whereas biochemical urinary analyses were mostly suggestive of prerenal aggression [8]. The author mentioned, according to their local protocol, including a decrease in fluid load (199.5 [1,962.8] vs 2,070 [1,975] mL; $P < .01$) and PEEP levels (10 [3] vs 12 [4] cm H₂O; $P < .01$), was associated with a decrease in IAP (13.5 [4] vs 23.0 [8] mm Hg; $P < 0.01$) and an increase in daily diuresis (1,510 [1,010] vs 925 [528] mL; $P < .01$) within 5 days [8].

obesity, which concerns a large subset of critically ill patients with COVID-19, is an independent risk factor of IAH [8-9]. The use of high PEEP level in patients with almost normal compliance has been widely criticized because it might increase transpulmonary pressures and decrease venous return without improving oxygenation [8,10]. As PEEP adjustments are transmitted to the abdomen, the use of high PEEP has also been reported to promote IAH in patients under mechanical ventilation [8,11-12].

A liberal fluid therapy strategy might promote the development of visceral edema as well as right-sided heart failure, thus contributing to IAH [8,13]. Thus, the optimal fluid and respiratory stewardship remains to be established by prospective studies in COVID-19 patients with preserved pulmonary compliance to avoid the adverse effects of either underhydration or overhydration and positive pressure ventilation on kidney function in this setting [8,14].

A study [15], concluded: the combination of intra-abdominal hypertension (IAH, intra-abdominal pressure ≥ 12 mmHg) and hypoxic respiratory failure (HRF,

PaO₂/FiO₂ ratio < 300 mmHg), independently increased the odds of 28-day mortality, and reduced the number of ICU- and ventilation-free days [15].

A study [16], hypothesis is that open abdomen (OA) may have a pivotal role in improving bowel microcirculation reducing the endothelial and the systemic cytokine-related damage in COVID19 patient. According to that study, during this pandemic, they managed several COVID-19 patients presenting with gastrointestinal manifestations, such as colitis (11 patients), bowel perforation (3 patients) and ischemia (3 patients). Some of these patients underwent an OA treatment for surgical complications - eg. abdominal compartmental syndrome (ACS) – and showed a rapid improvement of both respiratory and gut dysfunction [16].

The author mentioned [16]: Based on this concept, even if just anecdotal, our cases show that as first OA can improve the arterial and venous blood flow in the gastrointestinal tract by reducing IAP. Moreover, negative pressure therapy (NPT) allows cytokine clearance leading to a reduction of vascular endothelial damage. Both of these mechanisms might potentially improve microcirculation conditions determining an optimization of systemic perfusion and organ function [16].

It is a report [17] of a subject with a positive test for coronavirus disease 2019 (COVID-19), and abdominal pain. Physical examination revealed a distended and diffusely tender abdomen without guarding. Computed tomography of abdomen showed descending and sigmoid colon wall thickening and mid-ascending colon pneumatosis without portal venous gas. This was suggestive of COVID-19–induced ischemic colitis with partial bowel obstruction in the absence of other provoking factors [17].

Pneumatosis intestinalis is an uncommon condition identified by multiple gas-filled cysts in the intestinal submucosa/serosa on imaging. Rupture of these cysts causes pneumoperitoneum, which mandates emergent surgical intervention. The pathophysiology of this condition is still under speculation; however, it has been associated with many gastrointestinal and pulmonary conditions [17]. Because of this patient's absence of initial respiratory symptoms, the hypercoagulability and thromboinflammation associated with COVID-19 may be the culprit leading to bowel ischemia [17].

Patient self-inflicted lung injury (P-SILI) is generated by intense inspiratory effort yielding: (A) swings in transpulmonary pressure (i.e. lung stress) causing the inflation of big volumes in an aerated compartment markedly reduced by the disease-induced aeration loss; (B) abnormal increases in transvascular pressure, favoring negative-pressure pulmonary edema; (C) an intra-tidal shift of gas between different lung zones, generated by different transmission of muscular force (i.e. pendelluft); (D) diaphragm injury [18]. During

noninvasive support, careful clinical monitoring remains mandatory for prompt detection of treatment failure, in order not to delay intubation and protective ventilation [18].

Conclusion

In conclusion, change in transpulmonary pressures, respiratory drive, superinfection by necrotizing pneumonia, bacterial and fungal infections, direct effect of virus, effects of ventilator on manifestation and occurrence of barotrauma, need more investigation. Meanwhile portable chest X ray may not be appropriate enough to detect pneumothorax and patient not stable hemodynamically to be sent for chest CT scan to detect occult pneumothorax, and not appropriate enough for sonography in case of obesity and hyperaeration of lungs. Frequent chest auscultation and physical exams help not to miss suspected barotrauma. Also, assessment of occurrence of barotraumas in what time of infection and admission need more studies.

References

- [1] Perlman S. Another Decade, Another Coronavirus. *N Engl J Med.* 2020; 382(8):760-762.
- [2] McGuinness G, Zhan C, Rosenberg N, Azour L, Wickstrom M, Mason DM, et al. Increased Incidence of Barotrauma in Patients with COVID-19 on Invasive Mechanical Ventilation. *Radiology.* 2020; 297(2):E252-E262.
- [3] Gattinoni L, Marini JJ, Camporota L. The Respiratory Drive: An Overlooked Tile of COVID-19 Pathophysiology. *Am J Respir Crit Care Med.* 2020; 202(8):1079-1080.
- [4] Koyner JL, Murray PT. Mechanical ventilation and the kidney. *Blood Purif.* 2010;29(1):52-68.
- [5] Doty JM, Saggi BH, Blocher CR, Fakhry I, Gehr T, Sica D, et al. Effects of increased renal parenchymal pressure on renal function. *J Trauma.* 2000; 48(5): 874-877.
- [6] Sugerman HJ. Effects of increased intra-abdominal pressure in severe obesity. *Surg Clin North Am.* 2001; 81: 1063-75.
- [7] Shear W, Rosner MH. Acute kidney dysfunction secondary to the abdominal compartment syndrome. *J Nephrol.* 2006; 19(5):556-65.
- [8] Dupont V, Gamblin C, Bard M, Julien G, Bonnard M, Champenois V, et al. Severe Intraabdominal Hypertension in Critically Ill COVID-19 Patients With Acute Kidney Injury. *Chest.* 2021; 160(2):558-561.
- [9] Dupont V, Debrumetz A, Leguillou A, Morland D, Wynckel A, Colosio C, et al. Intra-abdominal hypertension in early post-kidney transplantation period is associated with impaired graft function. *Nephrol Dial Transplant.* 2020; 35(9):1619–1628.
- [10] Marini JJ, Gattinoni L. Management of COVID-19

- Respiratory Distress. *JAMA*. 2020; 323(22):2329-2330.
- [11] Reintam Blaser A, Regli A, De Keulenaer B, Kimball EJ, Starkopf L, Davis WA, et al. Incidence, Risk Factors, and Outcomes of Intra-Abdominal (IROI) Study Investigators. Incidence, Risk Factors, and Outcomes of Intra-Abdominal Hypertension in Critically Ill Patients-A Prospective Multicenter Study (IROI Study). *Crit Care Med*. 2019; 47(4):535-542.
- [12] Kirkpatrick AW, Roberts DJ, De Waele J, Jaeschke R, Malbrain ML, De Keulenaer B, et al. Pediatric Guidelines Sub-Committee for the World Society of the Abdominal Compartment Syndrome. Intra-abdominal hypertension and the abdominal compartment syndrome: updated consensus definitions and clinical practice guidelines from the World Society of the Abdominal Compartment Syndrome. *Intensive Care Med*. 2013; 39(7):1190-206.
- [13] Doyen D, Dupland P, Morand L, Fourrier E, Saccheri C, Buscot M, et al. Characteristics of cardiac injury in critically ill patients with coronavirus disease 2019. *Chest*. 2021; 159(5):1974-85.
- [14] Ostermann M, Liu K, Kashani K. Fluid Management in Acute Kidney Injury. *Chest*. 2019; 156(3):594-603.
- [15] Regli A, Reintam Blaser A, De Keulenaer B, Starkopf J, Kimball E, Malbrain MLNG, et al. Intra-abdominal hypertension and hypoxic respiratory failure together predict adverse outcome - A sub-analysis of a prospective cohort. *J Crit Care*. 2021; 64:165-172.
- [16] Di Grezia M, Fransvea P, Santullo F, Tirelli F, Fico V, Mirco P, et al. Intra-abdominal hypertension as a trigger of "gut failure" in SARS-CoV-2 infection: Effect of open abdomen (OA) and negative pressure therapy (NPT) on respiratory and gastrointestinal (GI) function. *Med Hypotheses*. 2020; 144:109954.
- [17] Lakshmanan S, Toubia N. Pneumatosis Intestinalis in COVID-19. *Clin Gastroenterol Hepatol*. 2021; 19(10):e99.
- [18] Grieco DL, Menga LS, Eleuteri D, Antonelli M. Patient self-inflicted lung injury: implications for acute hypoxemic respiratory failure and ARDS patients on non-invasive support. *Minerva Anesthesiol*. 2019; 85(9):1014-1023.