

SVC Syndrome in ICU: The Need of a Multidisciplinary Approach

Surabhi Sandill, Bhavya Krishna*, Santvana Kohli, Binita Jaiswal

Department of Anaesthesiology and Critical Care, Vardhman Mahavir Medical College and Safdarjung Hospital, New Delhi, India.

ARTICLE INFO

Article history:

Received 12 November 2021

Revised 03 December 2021

Accepted 17 December 2021

Keywords:

Superior vena cava syndrome (SVC);

Multidisciplinary team;

Mediastinal mass

ABSTRACT

Superior vena cava (SVC) syndrome, a potentially life threatening medical emergency, occurs due to SVC obstruction caused by extrinsic compression, intrinsic stenosis or thrombosis. Malignant mediastinal tumours account for more than 80% of cases of SVC syndrome. We hereby report a case of SVC syndrome who came with clinical features suggestive of SVC syndrome with dyspnea managed and diagnosed in the Intensive Care Unit with a multidisciplinary approach.

SVC syndrome is a clinical manifestation of SVC obstruction (partial or complete) resulting from impaired venous return to the heart from head, neck, thorax and upper extremities [1]. The signs and symptoms include breathlessness, intractable cough, facial and upper extremity swelling, flushing, distended veins, chest pain, dysphagia or stridor [2]. The obstruction of blood flow through SVC can be caused by direct invasion of a tumour into the vessel wall, external compression of a tumour mass against SVC or intravascular thrombosis [3-4]. Commonly, SVC syndrome is seen secondary to malignancies such as non-small cell lung cancer (50%), small cell lung cancer (25%) and non-Hodgkin's lymphoma (10%) [5].

There is paucity of literature regarding SVC syndrome in Indian population requiring critical care management. This report highlights the importance of an early ICU admission of such patients, a multidisciplinary approach to facilitate timely diagnosis and management of this condition, and a basic outline regarding its management.

Case Report

We obtained written informed consent from the patient.

A 61 year old male, chronic smoker, was referred to our hospital with complaints of cough, abdominal distension, generalised upper body swelling over 2 months and shortness of breath for the last 1 month. There was no associated history of fever, chest pain, palpitations, reduced urine output or yellowing of eyes/skin. There were no other comorbidities or any significant drug history, including alcohol. In view of severe dyspnoea, the patient was shifted to ICU for further management.

On reception in ICU, his Glasgow Coma Scale (GCS) was 15/15 with full orientation, pulse rate was 116/min, non-invasive blood pressure (NIBP) was 188/120 mmHg on the right arm, but 85/40 on the left arm, and oxygen saturation of 94% on venturi mask with 40% inspired oxygen. The general physical examination demonstrated facial flushing, distended veins on the chest and abdomen (depicted in Figure 1) with above downwards filling, swelling of the upper body and hydrocele. On chest auscultation, there was decreased air entry over the right upper zone of the lung. Since the patient was tachypneic (respiratory rate 35/min) with use of accessory muscles of respiration, it was decided to intubate the trachea and institute mechanical ventilation (pressure support), adjusted to serious blood gas analyses.

The authors declare no conflicts of interest.

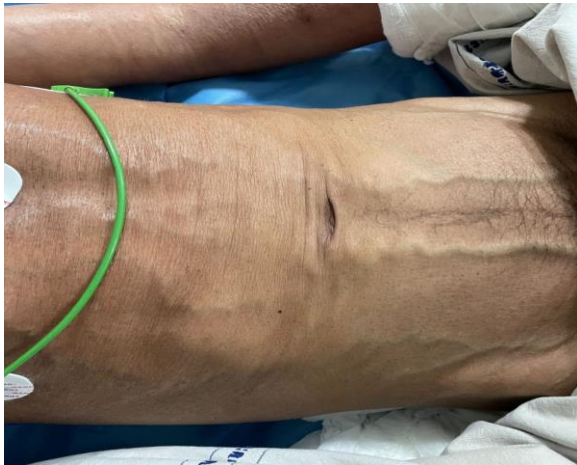*Corresponding author.

E-mail address: drkrishnabhavya@gmail.com

Copyright © 2022 Tehran University of Medical Sciences. Published by Tehran University of Medical Sciences.

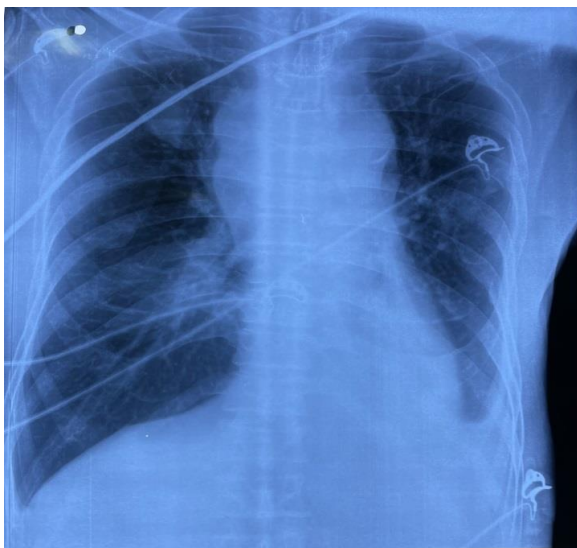


This work is licensed under a Creative Commons Attribution-NonCommercial 4.0 International license (<https://creativecommons.org/licenses/by-nc/4.0/>). Noncommercial uses of the work are permitted, provided the original work is properly cited.

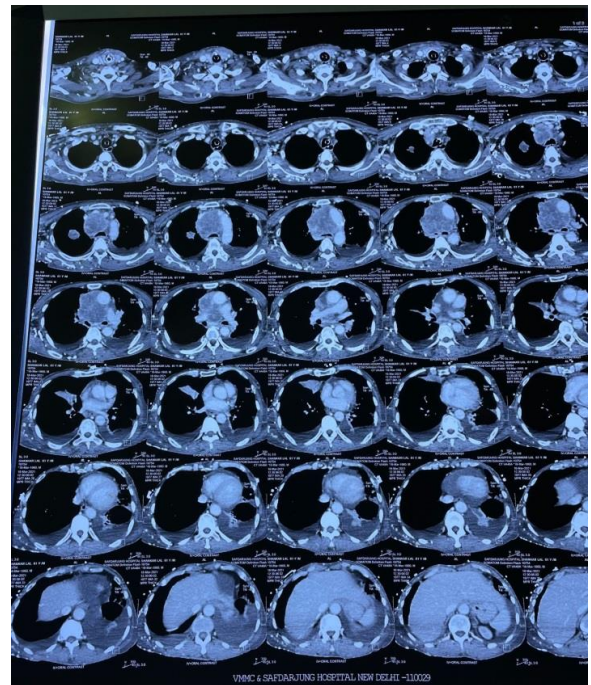
Figure 1- Patient's abdomen with visible dilated veins

Routine blood work ordered showed a haemoglobin of 11.4 g/dL and a white cell count of 20,200/cumm. His platelet counts, liver and kidney functions, serum electrolytes and coagulation profile were found to be within acceptable limits. Chest radiograph revealed gross mediastinal widening (Figure 2) and ultrasonography was suggestive of bilateral pleural effusion with pericardial effusion. Injectable Piperacillin-tazobactam and Clindamycin were prescribed for the patient, apart from steroids (dexamethasone), diuretics (furosemide), usual ICU sedation, ulceroprophylaxis and thromboprophylaxis. Early nasogastric feeding was planned.

Based on the presented history and examination findings, a provisional diagnosis of SVC syndrome was made and further work up was started in consultation with departments of respiratory medicine and radiology.

Figure 2- Chest radiograph showing mediastinal widening

Contrast-enhanced computed tomography (CECT) of thorax and abdomen was done on the following day, which revealed a lobulated mass in the upper lobe of the right lung with a large nodal mass in middle mediastinum. The nodal mass was found compressing the distal trachea and the right main bronchus, as well as invading into SVC causing complete occlusion and 270 degree encasement of ascending aorta and right pulmonary artery. There was evidence of left subclavian artery thrombosis explaining the discordance in blood pressure variation in both upper limbs. A provisional diagnosis of malignant lung mass with mediastinal nodal metastasis, causing SVC syndrome was formulated (Figure 3). Anti-thrombosis was started with therapeutic doses of low molecular weight heparin (enoxaparin 0.6ml subcutaneous twice a day), aspirin and oral warfarin 2mg once a day with coagulation monitoring, after consultation with cardiology and cardiac surgery.

Figure 3- CECT of thorax of patient showing malignant mass in the right lung with mediastinal lymph node involvement.

After discussion with pathologists, an ultrasound guided bilateral pleural tap was performed for differential count, malignant cytology along with malignant cell block. Smears showed moderate cellularity comprising mainly of reactive mesothelial cells and polymorphs with a few lymphocytes. However, no definitive evidence of malignant cells was seen in the smears. After a thorough multi-disciplinary discussion, a fiberoptic bronchoscopy with transbronchial lung biopsy was planned for the patient. The histopathology was consistent with squamous cell carcinoma lung. Chemoradiation was initiated. The patient's condition improved within days.

He was extubated and discharged from the hospital. He continued with his oncology follow up.

Discussion

Superior vena cava syndrome is a rare emergency, commonly encountered in patients with lung malignancies [6]. Depending on the degree of SVC obstruction, the patient may present with mild symptoms to life threatening conditions such as laryngeal oedema and airway compromise [7]. The key to successful management of such patients is an early recognition of the condition by way of a proper history and examination and early ICU admission. It is prudent that inputs from other disciplines like radiology, pathology, respiratory medicine, cardiology and cardio-thoracic surgery are sought in a timely manner for this complex disease entity.

The mainstays of treatment, once diagnosis has been established, include chemotherapy, radiation, endovascular stenting and corticosteroids [8-9]. Anticoagulation or thrombolytic therapy is indicated in thrombosis related SVC syndrome [10]. The subject of this case report presented with typical signs and symptoms of SVC syndrome. CECT thorax proved to be a useful diagnostic tool. A fibre optic guided biopsy confirmed the diagnosis and treatment was initiated accordingly.

Conclusion

SVC syndrome, though not very common, is a scenario we can encounter in our ICUs. With this case report we hope to highlight the diagnosis, workup and basic management of SVC syndrome and highlight the importance of an early critical care admission as well as collaboration between various involved disciplines.

References

- [1] Gucalp R, Dutcher JP. Oncologic emergency. In: *Harrisons Principles of Internal Medicine*. 19th ed. Mc Graw-Hill Education USA. 2015;2(19):1787.
- [2] Rice TW, Rodriguez RM, Light RW. The superior vena cava syndrome: Clinical characteristics and evolving etiology. *Medicine*. 2006; 85:37–42
- [3] Friedman T, Quencer KB, Kishore SA, et al. Malignant Venous Obstruction: Superior Vena Cava Syndrome and Beyond. *Semin Intervent Radiol* 2017; 34:398.
- [4] Kalra M, Sen I, Gloviczki P. Endovenous and Operative Treatment of Superior Vena Cava Syndrome. *Surg Clin North Am*. 2018; 98:321.
- [5] Jumean K, Hawatmeh A, Arqoub A, Shaaban H. Superior vena cava syndrome as a clinical manifestation of recurrent cervical cancer. *Lung India*. 2016; 33:246-7.
- [6] Devarakonda S, Morgensztern D, Govindan R. Superior Vena Cava Syndrome. In: *The Washington Manual of Medical Therapeutic*. 35th ed. Wolters Kluwer (India) 2016;(35):724.
- [7] Yu JB, Wilson LD, Detterbeck FC: Superior vena cava syndrome: a proposed classification system and algorithm for management. *J Thorac Oncol*. 2008; 3: 811–814.
- [8] Rowell NP, Gleeson FV. Steroids, radiotherapy, chemotherapy and stents for superior vena caval obstruction in carcinoma of the bronchus: A systematic review. *Clin Oncol (R Coll Radiol)* 2002; 14:338-51.
- [9] Kvale PA, Selecky PA, Prakash UB. American College of Chest Physicians. Palliative care in lung cancer: ACCP evidence-based clinical practice guidelines, (2nd edition). *Chest* 2007;132(Suppl):368S-403.
- [10] Wilson LD, Detterbeck FC, Yahalom J. Clinical practice. Superior vena cava syndrome with malignant causes. *N Engl J Med* 2007; 356:1862-9.