

# Total Intravenous Anaesthesia with Propofol and Dexmedetomidine for Brachial Plexus Repair with Intraoperative Neuromuscular Monitoring: A Case Series

Amartya Chaudhuri, Shital Kuttarmare\*, Pradnya Bhalerao, Neha Kamble

Department of Anaesthesiology, Byramjee Jeejeebhoy Govt. Medical College, Pune, India.

## ARTICLE INFO

### Article history:

Received 17 May 2022

Revised 08 Jun 2022

Accepted 23 Jun 2022

### Keywords:

Total intravenous anesthesia;  
Brachial plexus;  
Neuromuscular monitoring;  
Propofol;  
Dexmedetomidine

## ABSTRACT

**Background:** Brachial plexus surgery requires neural repair with the use of intraoperative peripheral nerve stimulation without muscle relaxants.

**Methods:** Twelve cases were conducted under total intravenous anaesthesia, receiving intravenous propofol, fentanyl and dexmedetomidine infusion. Intraoperative hemodynamic conditions and postoperative functional recovery were assessed.

**Results:** 9 out of 12 cases were stable while one was in a lighter plane requiring 20 mg propofol and increased dexmedetomidine, two had bradycardia requiring reduced dexmedetomidine infusion. At three months, five cases showed improvement.

**Conclusion:** Satisfactory conditions were achieved including hemodynamic stability, and muscle-sparing improving prognoses of brachial plexus surgeries.

More than one-third of all peripheral nerve injuries involve brachial plexus injury, and brachial plexopathy make up for 2% of all patients presenting to trauma facility and 5% if root involvements are included [1-2]. It affects males more than females, and the median age is 34 years. The most common mode of injury is due to high energy forces such as road traffic accidents, which result in closed traction (the most common mechanism) leading to section/contusion/ stretch injuries of neural tissues. In addition, cervical nerve root injuries close to the spinal cord can occur in traumatic brachial plexopathy patients [3]. Brachial plexus surgery requires intricate neural tissue repair, which shows better prognostic value over the last few decades due to the advent of multiple surgical methods [4]. However, full functional recovery is seldom achievable surgically. Historically, brachial plexus surgeries failed to provide any significant prognostic improvement [5]. Therefore, supplementing surgical interventions with more accurate intraoperative tissue identification with neurophysiological monitoring became pertinent. For this purpose, intraoperative

identification of neural tissue and its integrity by direct peripheral nerve stimulation has become increasingly popular. In case of a gross traumatic anatomical disturbance where nerve identification is difficult, direct nerve stimulation uses the neurophysiological nature of otherwise unidentifiable neural tissue to locate and repair surgically [6]. With such accuracy, the postoperative prognosis of functional improvement in these patients are better. Peripheral nerve stimulation needle uses a direct periodic electrical stimulation (1 mA amplitude, 2 Hertz frequency) of neural tissue and identifies the nerve from observing the group of muscles that contracts as a response [7]. As basic physiology suggests, this technique is only useful if the muscles under observation are not paralyzed. So, the surgeons require a mode of anaesthesia that spares skeletal muscles from paralysis. Although regional anaesthesia has better hemodynamic stability, stronger postoperative analgesia and lower mortality, it is less preferred here due to the medicolegal aspect of resultant postoperative brachial plexopathy in some trauma patients [8].

The authors declare no conflicts of interest.

\*Corresponding author.

E-mail address: [shital.kuttarmare1123@gmail.com](mailto:shital.kuttarmare1123@gmail.com)

Copyright © 2023 Tehran University of Medical Sciences. Published by Tehran University of Medical Sciences.



This work is licensed under a Creative Commons Attribution-NonCommercial 4.0 International license (<https://creativecommons.org/licenses/by-nc/4.0/>). Noncommercial uses of the work are permitted, provided the original work is properly cited.

Here we present a series of 12 cases taken for brachial plexus repair under total intravenous anaesthesia and management of hemodynamic stability.

## Methods

This non-formal case series, conducted in a tertiary care centre between June 2019 and May 2021 describes a total of 12 cases. Patients belonging to the American Society of Anesthesiologists (ASA) grade I and II physical status, between the age of 18 and 65 years, of either sex were included for this case series with their consent. Patients with uncontrolled cardiovascular comorbidities such as hypertension, diabetes mellitus and ischaemic heart diseases, severe and morbid obesity, history of cerebrovascular accidents, lab-confirmed Reverse Transcriptase Polymerase Chain Reaction (RT-PCR) test positive coronavirus disease (COVID-19) pneumonitis were excluded, but keeping in mind the semi-emergent nature of the repair surgeries, patients with a previous history of COVID-19 pneumonitis were included, provided their functional status and coagulation profile were within normal limits. Patients below 18 years of age and above 65 years of age were excluded too. Patients with a history of bronchial asthma, anticipated difficult airway (Mallampati grading 3 and 4) and history of allergic reaction to the medications were excluded.

All patients were subjected to a period of physiotherapy before the operative procedure was finally decided as the only determinant for a better prognosis. Preoperative assessment of motor function was carried out clinically using Medical Research Council (MRC) Grades (where G5= Excellent, G3 – 4= Good, G2= Fair and G0 – 1=Poor). These patients were then investigated for routine hemogram, leucocyte and platelet count, hematocrit, serum electrolytes, renal function tests and liver function tests. Roentgenograms of chests, shoulders, and necks were done along with computed tomography scan (CT scan), myelogram and electromyography (EMG), magnetic resonance imaging (MRI) of the surgical site where indicated. Baseline twelve-lead-electrocardiograms (ECG) was done. The advantages and risks of surgical procedures and anaesthetic management were explained to all patients before surgery. After confirming nil per oral (NPO) status, patients were taken inside the operation theatre and monitors such as pulse oximetry, electrocardiography, non-invasive blood pressure were attached. Patients were given supine position and intravenous lactated ringers solution infusion started at a rate of 200 cc per hour. Injection Glycopyrrolate 5 µg/kg, injection Midazolam 0.03 mg/kg, injection Fentanyl 2 µg/kg were given intravenously. Preoxygenation was done with 100% oxygen for 3 minutes. In-line End-tidal Carbon dioxide (EtCO<sub>2</sub>) measuring was initiated. Patients were induced with intravenous injection Propofol 2 mg/kg followed by injection Suxamethonium 2 mg/kg. Intermittent positive pressure bag-mask ventilation was started with a closed circuit. After full jaw relaxation, laryngoscopy was done

with Macintosh blade (male: size 4 and female: size 3) and patients were intubated with Portex endotracheal tubes (male: 8 mm internal diameter, and female: 7.5 mm). Following auscultation of bilateral air entry, the endotracheal tube was fixed securely. Volume controlled mechanical ventilation was initiated with 6 ml/kg tidal volume of a gas mixture containing 1:1 ratio Oxygen and Nitrous Oxide. Positive end-expiratory pressure (PEEP) of 5 cm water was maintained and rate of breath was modulated to achieve and maintain an EtCO<sub>2</sub> of 25 – 35 mm Hg. Nasogastric tubes were inserted, and Foley's catheterization was done. Five out of the twelve surgeries were performed in the prone position. Respiratory circuit stability, throat packing, eye padding, protection of bony prominences and face was all taken care of before proning. After proning, the PEEP value was set to 0. Patients were given injection Dexmedetomidine 1 µg/kg over 15 minutes followed by infusion at the rate of 0.5 µg/kg/hour. A range of variation of infusion rate from 0.2 to 0.7 µg/kg/hour was allowed for all patients for maintaining the plane of anaesthesia. An additional dose of 20 µg fentanyl was repeated intraoperatively at the end of 1st hour. Intravenous injection Paracetamol 500 mg and injection Tramadol 100 mg were given as analgesics at the time of incision and 2-hours mark in the intraoperative period. Dexmedetomidine infusion was stopped 30 minutes before the end of surgery. At the end of the surgeries done in the prone position, patients were made supine taking care of respiratory circuit and monitor wires, throat packs and eye pads were removed and patients were extubated in deep inspiration. In Post Anaesthesia Care Unit (PACU), patients were observed till they achieved a modified Aldrete score of 10. Then patients were shifted to the ward and at the end of the 8th postoperative hour, clear fluids were given. With good recovery, patients were subsequently discharged in 5-6 days. Patients were followed up for motor function improvement and pain relief for 3 months on an outpatient basis.

## Results

Brachial plexus injury was observed to be more common among males than females (3:1), and age distribution followed a bell curve distribution with a peak at 30-35 years of age (Figure 1). Pan-brachial plexopathy (5 cases) was more common than partial injuries to the upper (4 cases) or lower (3 cases) parts of the brachial plexus (Figure 2). Road traffic accident (7 cases) was the most common cause of brachial plexopathy, followed by fall from height (4 cases). A road-traffic accident patient had associated injury to the 1st and 2nd ribs of the same side, and two others had fractures involving lower limbs of the same side. Neural tissue suffered a stretch injury (3 cases), compression injury (3 cases), avulsion injury (3 cases), laceration injury (2 cases) and incisional injury (1 case). Out of these 12 cases, 5 cases were submitted for neurolysis only, 5 cases for nerve transfer, and 2 cases for neurolysis+ nerve transfer+ grafting.

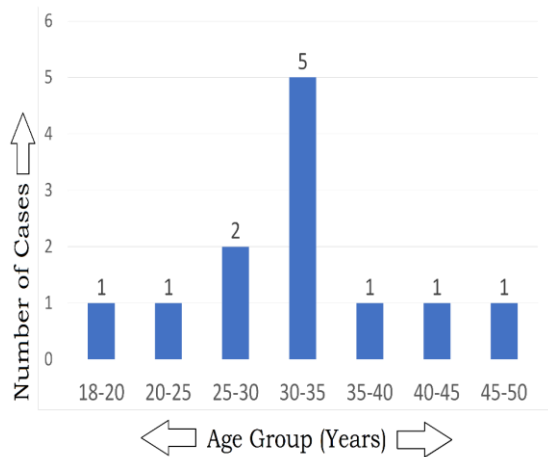


Figure 1- Number of cases in the age group in the series

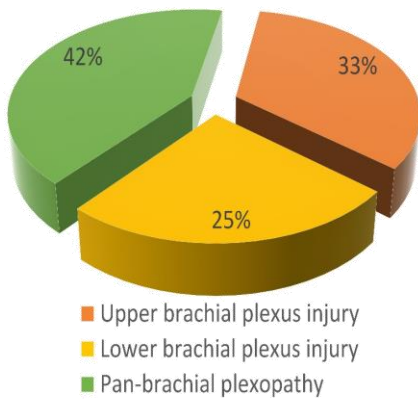


Figure 2: Distribution of type of injuries of brachial plexus in case series

Figure 2- Distribution of type of injuries of brachial plexus in case series

Post-operatively all 12 patients were followed up for 3 months for assessment of motor and sensory improvement. 3 months after the surgery, postoperative motor function was assessed using MRC grades. Any score of G3 or more was considered as significant improvement and 5 cases (3 cases of neurolysis only, 1 case of nerve transfer and 1 neurolysis plus nerve transfer and grafting) were observed to show significant improvement (Figure 3) and 7 cases did not show any such improvement.

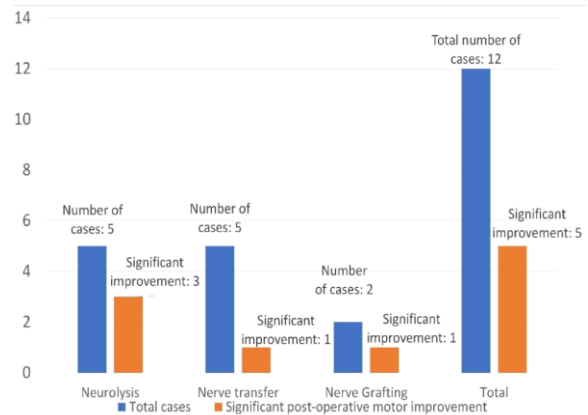


Figure 3- Success rate of different surgical interventions for brachial plexus injury in the case series at 3 months postoperative checkup

Vitals were stable for 9 out of 12 patients.

One patient had tachycardia and hypertension during the intraoperative period. The patient was assessed to be in a lighter plane of anaesthesia for which 20 mg of intravenous injection propofol was given and the rate of intravenous Dexmedetomidine infusion was increased to 0.7 µg/kg/hour. The patient achieved desired depth of sedation within 3 minutes and maintained it throughout the rest of the intraoperative period.

Two patients had bradycardia during the intraoperative period. It was evaluated to be a result of a deeper plane of anaesthesia. Dexmedetomidine infusion was slowed down to 0.2 µg/kg/hour. Injection atropine 0.6 mg was loaded, and injection of isoprenaline 1 mg in 50 cc syringe was loaded in infusion pump and kept ready for infusion at 15 cc/hour (5 µg/min) rate. However, both patients achieved desired hemodynamic stability and depth of sedation in less than 15 minutes, without interventions with atropine or isoprenaline (Figure 4).

Diagram 4: Chart showing trend of intraoperative heart rates of 12 cases recorded during 0 - 120 minutes at 15-minute intervals (Original)

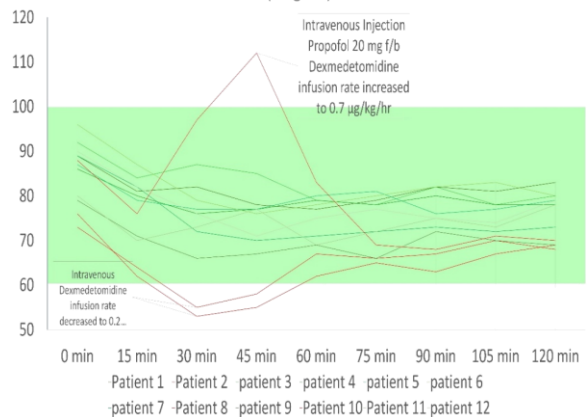


Figure 4- Chart showing trend of intraoperative heart rates of 12 cases recorded during 0 – 120 minutes at 15 minute interval.

## Discussion

Brachial plexus repair surgeries require the identification of nerves in a background of distorted anatomy, as the cause of injuries is frequently traumatic [3]. It is therefore a challenge for surgeons to identify them under visual guidance accurately. But even with distorted anatomy, many of these nerve endings are found to be functional. Correct identification of these nerves and subsequent surgical repair can often lead to a better prognosis in terms of motor activity, sensory inputs and overall quality of life [9]. Therefore, it was prudent for surgeons to achieve greater accuracy while identification of neural tissue.

A peripheral nerve stimulator (PNS) delivers short waves of direct current at a fixed interval of time. The amplitude of the current can be titrated according to the degree of accuracy needed to identify nerves. A PNS system attached to a 5 cm PNS needle was used to identify the nerves. The short delivery of direct current generates action potential in excitable tissue (viable muscles and nerves) which in turn generates muscle contraction. By observing the group of muscles responding to a particular electrical stimulus, we can identify the nerve stimulated by the PNS system. This principle is used to identify viable nerves and perform the repair [10]. Visually unidentifiable nerves can be salvaged in this way, leaving a better prognosis for the patient.

A pre-requisite for such a procedure is the obvious abstinence of the use of skeletal muscle relaxants, which prevents muscle excitability, rendering the exercise pointless. Thus, avoiding skeletal muscle relaxants is a basic requirement of nerve repair procedures using PNS. In the absence of muscle relaxants, the patients have a higher tendency of ventilator desynchrony, increased sympathetic tone, hemodynamic instability, awareness during anaesthesia and voluntary motor responses that may hamper intricate operations such as the one in the study. Thus it is crucial to supplement with deep sedation which can prevent these undesirable effects. Dexmedetomidine, Propofol and Fentanyl are some options we explored to evaluate their role in hemodynamic stability, analgesia and deep sedation.

Dexmedetomidine is an  $\alpha_2$ -adrenergic receptor ( $\alpha_2$ -AR) agonist with high selectivity, having sedative and analgesic effects, reduced agitation and delirium, perioperative sympatholysis with cardiovascular stabilizing effects, and a preserved respiratory function [11]. Dexmedetomidine has been proven to have significantly reduced pain scores when compared to propofol and sevoflurane [12] according to recent studies. It was ideal as a measure for strong analgesia for brachial plexus surgeries where other forms of sedation and muscle relaxants were avoided. Dexmedetomidine has a high sedation score also. It was therefore sufficient as a

measure of sedation where inhalational anaesthetic agents were avoided. Dexmedetomidine may cause a higher level of postoperative sedation [13]. For this reason, it was prudent to monitor the patients in a post anaesthesia care unit during a postoperative period of 2 hours. While postoperative sedation is a concern, it should be noted that Dexmedetomidine reduces delirium and agitation in post-operative patients. It also decreases the respiratory rate and results in increased CO<sub>2</sub> in the patients. Hypercapnia driven ventilatory drive helps arousal of respiratory functions at the end of the operative procedure [14]. Hemodynamic stability achieved with Dexmedetomidine is satisfactory.

Isoprenaline is a  $\beta_1$  and  $\beta_2$  adrenergic receptor agonist.  $\beta_1$  agonist activity leads to positive inotropy, lusitropy, chronotropy and dromotropy, all of which are helpful in Dexmedetomidine induced bradycardia and hypotension.  $\beta_2$  agonism leads to peripheral vasodilation and bronchial, gastrointestinal and genitourinary smooth muscle relaxation [15].

Propofol acts as both  $\gamma$ -Aminobutyric-Acid A (GABAA) receptor positive allosteric modulator and agonist, increasing the channel closing time and activating it, to impart sedative-hypnotic effect. Propofol has a rapid onset of action, short context-sensitive half-time and short effect-site equilibration time, making it ideal for readily titratable IV sedation. It shows the prompt recovery, no residual sedation, and antiemetic action and thus it was chosen for induction and as bolus dose for deepening plane of anaesthesia in one patient who initially had an insufficient rate of dexmedetomidine infusion [16].

Fentanyl is a phenylpiperidine-derivative synthetic opioid agonist, with strong analgesic and sedative action. It has good lipid solubility and a large volume of distribution, a 6.4-minute-long effect-site equilibration time, and a rapid redistribution to fat and skeletal muscles, leading to its rapid onset of action, greater potency, delayed peak of action, short duration of action. Long infusions or repeated doses can lead to prolonged duration of action and depression of ventilation. We have used fentanyl during induction of anaesthesia for both analgesic and sedative action and repeated a 20- $\mu$ g intravenous dose at the end of 1st hour to impart analgesic effect without causing respiratory depression and post-operative requirement of ventilatory support [17].

With deep sedation, an assessment of plane of anaesthesia by means of bispectral index (BIS) monitoring is useful. The scope of our study was limited due to unavailability of BIS monitoring. With intraoperative BIS monitoring, postoperative residual sedation and analgesic requirement is also less, reducing the need for PACU monitoring and opioid requirement [18].



## Conclusion

Brachial plexus surgeries are intricate and demanding of accurate surgical interventions, so nerve identification with PNS can bring a better outcome to patients. Total intravenous anaesthesia is a good fit for surgical procedures where skeletal muscle paralysis is spared. Anaesthetic concerns in these patients are: maintaining a deep plane of anaesthesia, hemodynamic stability, strong intra- and postoperative analgesia, and anxiolysis, with attention to attenuating sympathetic responses, eliminating postoperative nausea, vomiting and prolonged depression of ventilation. Intraoperative BIS monitoring can prove useful. Post-anaesthetic evaluation with Aldrete score provided a systemic approach for determining residual sedation before shifting back to the ward. The 3-month-interval postoperative checkup revealed a fair prognosis of PNS guided brachial plexus repair.

## References

- [1] Bertelli JA, Ghizoni MF. Results and current approach for Brachial Plexus reconstruction. *Journal of brachial plexus and peripheral nerve injury*. 2011; 6(1):2.
- [2] Noble J, Munro CA, Prasad VS, Midha R. Analysis of upper and lower extremity peripheral nerve injuries in a population of patients with multiple injuries. *J Trauma*. 1998;45(1):116-122.
- [3] Kim DH, Murovic JA, Tiel RL, Kline DG. Mechanisms of injury in operative brachial plexus lesions. *Neurosurg Focus*. 2004 May 15;16(5):2.
- [4] Armas-Salazar A, García-Jerónimo AI, Villegas-López FA, Navarro-Olvera JL, Carrillo-Ruiz JD. Clinical outcomes report in different brachial plexus injury surgeries: a systematic review. *Neurosurg Rev*. 2022; 45(1):411-419.
- [5] Thatte MR, Babhulkar S, Hiremath A. Brachial plexus injury in adults: Diagnosis and surgical treatment strategies. *Ann Indian Acad Neurol*. 2013; 16(1):26-33.
- [6] Bhandari PS, Maurya S. Recent advances in the management of brachial plexus injuries. *Indian J Plast Surg*. 2014; 47(2):191-8.
- [7] Campbell WW. Evaluation and management of peripheral nerve injury. *Clin Neurophysiol*. 2008;119(9):1951-65.
- [8] Saba R, Brovman EY, Kang D, Greenberg P, Kaye AD, Urman RD. A Contemporary Medicolegal Analysis of Injury Related to Peripheral Nerve Blocks. *Pain Physician*. 2019; 22(4):389-400.
- [9] Menorca RM, Fussell TS, Elfar JC. Nerve physiology: mechanisms of injury and recovery. *Hand Clin*. 2013; 29(3):317-30.
- [10] David M. Polaner, Santhanam Suresh, Charles J. Coté, [book auth.] W.B. Saunders. *Regional Anesthesia*. In: Lerman Jerrold, Todres I David, Coté Charles J, editors. *A Practice of Anesthesia for Infants and Children*. 4th ed. Elsevier Publication; 2009. p. 867-910.
- [11] Kaur M, Singh P. Current role of dexmedetomidine in clinical anesthesia and intensive care. *Anesth Essays Res*. 2011; 5(2):128-33.
- [12] Mousa SA, Abd Elfatah Alsobky H. Efficacy and effect of TIVA with propofol or dexmedetomidine versus sevoflurane without muscle relaxant during repair of the brachial plexus. *Egyptian J Anaesthesia*. 2013; 29(1):31-40.
- [13] Park J-W, Kim E-K, Lee H-T, Park S, Do S-H. The Effects of Propofol or Dexmedetomidine Sedation on Postoperative Recovery in Elderly Patients Receiving Lower Limb Surgery under Spinal Anesthesia: A Retrospective Propensity Score-Matched Analysis. *J Clin Med*. 2021; 10(1):135.
- [14] Weerink MAS, Struys MMRF, Hannivoort LN, Barends CRM, Absalom AR, Colin P. Clinical Pharmacokinetics and Pharmacodynamics of Dexmedetomidine. *Clin Pharmacokinet*. 2017; 56(8):893-913.
- [15] Szymanski MW, Singh DP. Isoproterenol. [Updated 2021 Nov 8]. In: Treasure Island (FL), editor. In: StatPearls [Internet]. StatPearls Publishing; 2022.
- [16] Mah GT, Turgeon RD, Loh G, Tejani AM, Sweet DD. Ketamine and propofol in combination for adult procedural sedation and analgesia in the emergency department. *Cochrane Database Syst Rev*. 2015.
- [17] Akheela MK, Chandra A. Comparative Evaluation of Nalbuphine and Fentanyl for Attenuation of Pressor Response to Laryngoscopy and Tracheal Intubation in Laparoscopic Cholecystectomy. *Cureus*. 2021.
- [18] Sahni N, Anand LK, Gombar K, Gombar S. Effect of intraoperative depth of anesthesia on postoperative pain and analgesic requirement: A randomized prospective observer blinded study. *J Anaesthesiol Clin Pharmacol*. 2011; 27(4):500-5.