

# The Effect of Prophylactic Administration of Ketorolac Ophthalmic Suspension on Prevention of Surgically Induced Miosis in Patients Undergoing Cataract Surgery

Mehdi Sanatkar<sup>1</sup>, Mehrdad Goudarzi<sup>1</sup>, Hamed Ghassemi<sup>2\*</sup>, Mahsa Keyhanian<sup>3</sup>, Amir Abbas Yaghoobi<sup>1</sup>, Hossein Sadrossadat<sup>1</sup>, Reza Ghafari<sup>2</sup>, Shahrokh Ghazizadeh<sup>4</sup>, Hassan Mohammadi Poor Anvari<sup>5</sup>, Somaye Asadi<sup>6</sup>

**Background:** Cataract extraction surgery remains the most commonly performed eye surgery by ophthalmologists. The maintenance of mydriasis is required throughout surgery to allow better visualization of the surgical field and a greater working space within the center of the eye. Non-steroidal anti-inflammatory agents (NSAIDs) have their effect in maintaining mydriasis by their ability to inhibit prostaglandin synthesis.

**Methods:** This was a prospective, randomized clinical trial study in 84 patients undergoing phacoemulsification cataract surgery. Patients were randomized to ketorolac tromethamine 0.5% (n=42) or the control group (n=42). Patients in the ketorolac group received one drop of ketorolac every 15 min for a total of 4 drops from one hour before surgery. The horizontal diameters of the pupil were measured in millimeters with a caliper under the microscope at the following stages: before surgery, after intracameral epinephrine injection, after nuclear emulsification and at the end of surgery.

**Results:** The difference in pupillary diameter at the end of surgery was statistically significant between two groups ( $7.34 \pm 1.0$  mm and  $8.01 \pm 0.67$  mm in the control and the ketorolac groups, respectively;  $p=0.018$ ). The difference in mean pupil size after intracameral epinephrine injection and after nuclear emulsification between the control group ( $0.51 \pm 0.25$  mm) and the ketorolac group ( $0.01 \pm 0.20$  mm) was statistically significant ( $p < 0.001$ ). Moreover, the difference in mean pupil size after intracameral epinephrine injection and at the end of surgery between the control group ( $0.79 \pm 0.44$  mm) and the ketorolac group ( $0.19 \pm 0.23$  mm) was statistically significant ( $p < 0.001$ ). There was no difference in maintaining mydriasis between diabetic patients and non-diabetic patients.

**Conclusion:** Topical ketorolac is an effective inhibitor of miosis during phacoemulsification cataract surgery, and provides a more stable mydriatic effect throughout the surgical procedure.

**Keywords:** cataract surgery; ketorolac tromethamine; mydriasis; miosis; pupil diameter

The most commonly eye operation is the cataract extraction surgery [1]. The prevalence of this procedure increases with age [2]. Currently, the surgical choice for cataract surgery is the

phacoemulsification with intraocular lens (IOL) implantation [3]. The maintenance of mydriasis throughout the procedure is necessary and allows better visualization of the surgical field and decreasing trans-operative complications such as posterior capsule rupture [4]. Cataract extraction causes trigger inflammatory cascade and releases the inflammatory mediators such as cyclooxygenase-1 (COX-1) and COX-2 enzymes and prostaglandins (PGs) [5]. These mediators' cause pain, miosis, changes in intraocular pressure (IOP), posterior capsular opacity, and cystoid macular edema (CME) [5]. It was identified that use of non-steroidal anti-inflammatory drugs (NSAIDs) through inhibition of COX enzymes and topical corticosteroids with the resultant inhibition of PG release, could control the post cataract surgery inflammation [7-8]. Moreover, simultaneous use of these agents has synergistic effect for pain management and reduces the intraocular inflammation [9]. Previous study has shown that topical non-steroidal drops have also been found to maintain mydriasis during cataract extraction surgery [10]. Ketorolac is a topical NSAID that is effective in the treatment of pain and postoperative inflammation. The purpose of this study was

From the <sup>1</sup>Department of Anesthesiology and Critical Care, Tehran University of Medical Sciences, Farabi Eye Hospital, Tehran, Iran.

<sup>2</sup>Department of Ophthalmology, Tehran University of Medical Sciences, Farabi Eye Hospital, Tehran, Iran.

<sup>3</sup>General Physician of Faculty of Medicine, Tehran University of Medical Sciences, Tehran, Iran.

<sup>4</sup>Department of Surgery, Tehran University of Medical Sciences, Razi Hospital, Tehran, Iran.

<sup>5</sup>Department of Anesthesiology and Critical Care, Tabriz University of Medical Sciences, Imam Reza Hospital, Tabriz, Iran.

<sup>6</sup>BS Student of Nutrition/Ms Student in Health Management, Tehran University of Medical Sciences, Farabi Eye Hospital, Tehran, Iran.

Received: 10 February 2016, Revised: 4 March 2016, Accepted: 16 March 2016

The authors declare no conflicts of interest.

\*Corresponding author: Hamed Ghassemi, MD. Department of Ophthalmology, Tehran University of Medical Sciences, Farabi Eye Hospital, Tehran, Iran. E-mail: hamedghassemi@yahoo.com  
Copyright © 2016 Tehran University of Medical Sciences

to evaluate the efficacy of prophylactic injection of ketorolac drops 0.5% in addition to conventional topical mydriatics in maintaining intraoperative mydriasis during cataract surgery by phacoemulsification.

## Methods

This was a randomized and double blind clinical trial study in patients undergoing phacoemulsification cataract surgery and was performed to support the use of ketorolac 0.5% for maintaining mydriasis during surgery. Approval from the hospital ethical committee and written consent from all patients were obtained. Eighty four participants were included in this study. Patients who were 40 years of age or older and diagnosed with senile or metabolic cataract with classification NO and NC 2–3 and candidate to have cataract extraction by phacoemulsification and lens replacement and who had a baseline intraocular pressure (IOP) of 5 to 22 mm Hg with a normal funduscopy exam were enrolled in this study.

The exclusion criteria were as follows: history of infectious disease, significant systemic disease, dry eye, connective tissue disease, pregnancy, narrow-angle or unstable glaucoma, history of iritis or trauma to iris, ocular surgery, history of hypersensitivity to the preservatives, pseudoexfoliations, previous eye surgery (non-laser surgery within 3 months or laser surgery within 30 days prior to study surgery), use of topical or systemic steroids within 30 days, use of topical or systemic NSAIDs within 14 days prior, use of preoperative phenylephrine or ocular mast stabilizers within 7 days before study surgery, history of administration of pilocarpine within 6 months before surgery and use of  $\alpha$ 1-adrenergic antagonist. Also, patients with non-controlled diabetes mellitus or non-controlled hypertension and proliferative diabetic retinopathy were excluded from this study. All of our cases underwent an ophthalmic examination included slitlamp examination, measurement of IOP, fundus examination and visual acuity. Moreover, macular OCT, fast macular thickness map and total macular volume (TMV) were performed in our patients to detect any macular alteration.

Upon meeting eligibility requirements, our patients were randomized by computer generated random number table to ketorolac 0.5% (n=42) or placebo group (n=42). All of our patients, investigators and study-related personnel were blinded to study assignment. Preoperatively, mydriatic treatment was performed for all patients including mydriatic treatment with topical phenylephrine HCl 2.5% plus tropicamide 1.0%, 1 drop every 15 minutes (4 doses) in both groups. Additionally, 1 drop of ketorolac 0.5% was used one hour before surgery (every 15 minutes, 4 doses) in the ketorolac group. The primary endpoint of our study was intraoperative horizontal pupil diameter in millimeters with a caliper under the microscope during surgery at the following stages: before beginning of the operation, after intracameral epinephrine injection, after nuclear emulsification and at the end of cataract surgery.

Cataract surgery was performed by one experienced surgeon by phacoemulsification and IOL implantation inside the capsular bag under topical anesthesia with tetracaine 0.5% in all patients. Based on small-incision phacoemulsification technique, 2.8 mm temporal and 1.0 mm nasal corneal incisions were performed and a

capsulorhexis 5.0 mm in diameter was created in all participants. A pre-chopped phacoemulsification technique was used and foldable IOLs were implanted in the capsular bag. Cataract surgery was performed with the Infiniti system (Alcon Laboratories, Inc.) with parameters as follows: amplitude of 100%, balanced saline solution for irrigation, with the height of the bottle set at 110 cm, 38 ml/minute aspiration flow rate, 350 mmHg vacuum, and a dynamic rise of 1. All patients underwent surgery with the same microscope. Topical antibiotic-corticosteroid medication (chloramphenicol and betamethasone) was used 4 times daily for 10 days after operation in all patients. Our ophthalmologist evaluated all our patients at day 1 and at weeks 2 and 6 after surgery. At each follow-up visit the physician evaluated the IOP measurements, funduscopy and slitlamp examination in our entire participants.

## Statistical analysis

Statistical analysis was performed using the SPSS (version 14, Inc. Chicago, IL, USA) statistical software. Data from both groups were described as means values and proportions and continuous variables were analyzed using the ANOVA or t-test. Categorical data were analyzed with a chi-square test or Fisher exact test as appropriate. P-value < 0.05 was considered significant.

## Results

Eighty four patients were included in this study and randomly divided to two groups with forty two patients in each group. The average age of patients was  $61.8 \pm 9.7$  years (range, 40 to 88); 44 patients (52.3%) were male. The demographic characteristics of each group showed in (Table 1). The grade of cataract disease in our participants was compared between two groups (Table 2). Maintenance of mydriasis based on the average of preoperative horizontal pupillary diameter was compared between two groups (Table 3) (Figure 1). The difference in pupillary diameter at the end of surgery was statistically significant between two groups ( $7.34 \pm 1.0$  mm and  $8.01 \pm 0.67$  mm in the control and the ketorolac groups, respectively;  $p=0.018$ ).

The difference in mean pupil size after intracameral epinephrine injection and after nuclear emulsification between the control group ( $0.51 \pm 0.25$  mm) and the ketorolac group ( $0.01 \pm 0.20$  mm) was statistically significant ( $p < 0.001$ ). Also, the difference in mean pupil size after intracameral epinephrine injection and at the end of surgery between the control group ( $0.79 \pm 0.44$  mm) and the ketorolac group ( $0.19 \pm 0.23$  mm) was statistically significant ( $p < 0.001$ ). However, the difference in mean pupil size after nuclear emulsification and at the end of surgery between the control group ( $0.28 \pm 0.28$  mm) and the ketorolac group ( $0.20 \pm 0.29$  mm) was statistically significant ( $p = 0.35$ ) (Figure 2). The pupillary diameter was not associated with age and gender between two groups ( $p=0.97$ ). The pupil size diameter was analyzed in association with diabetes mellitus in two groups and we found that in our study there was no difference in maintaining mydriasis between diabetic patients and non-diabetic patients ( $p=0.34$ ). None of the patients developed clinically significant macular edema associated with vision loss in both groups.

**Table1- The comparison of demographic data between two groups**

Characteristics	Ketorolac Group	Control Group	p-value
Age (Yr)	61.9±10.8	61.86±9.72	0.98
Gender (male)	22	24	0.97
Diabetes	6	7	0.82
Hypertension	8	18	0.47
Eye under surgery (right)	20	28	0.88
Intraocular pressure (IOP)	16.1±4.8	16.8±5.6	0.33
Duration of operation (min)	10.0±1.23	9.76±0.93	0.46

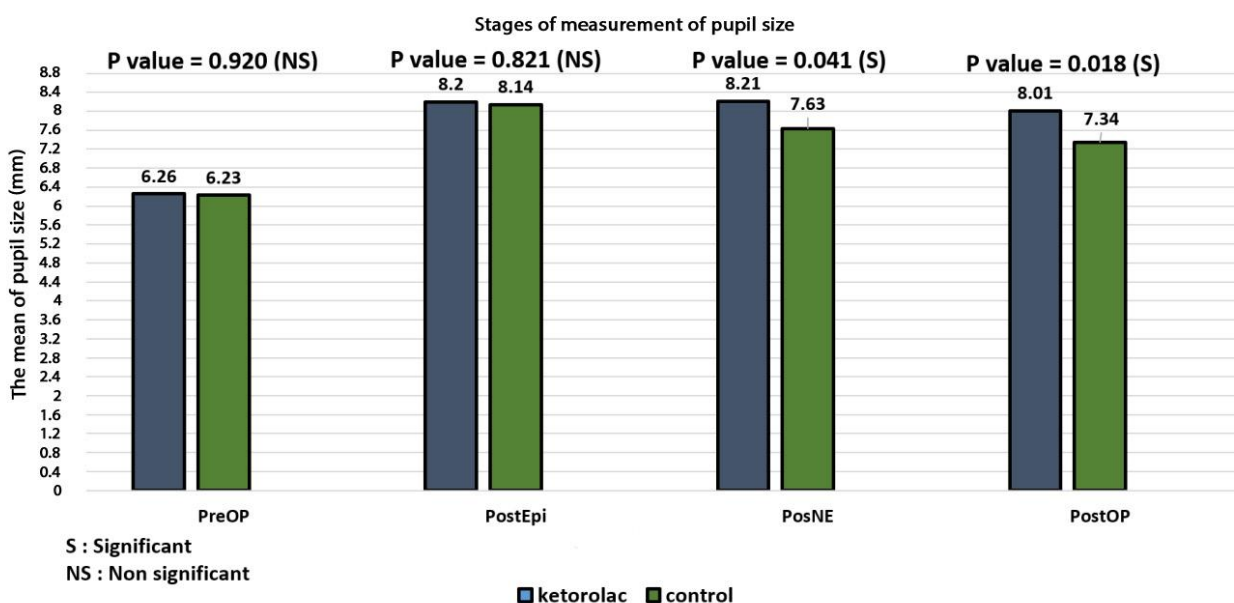
**Table2- The comparison of cataract grad between two groups**

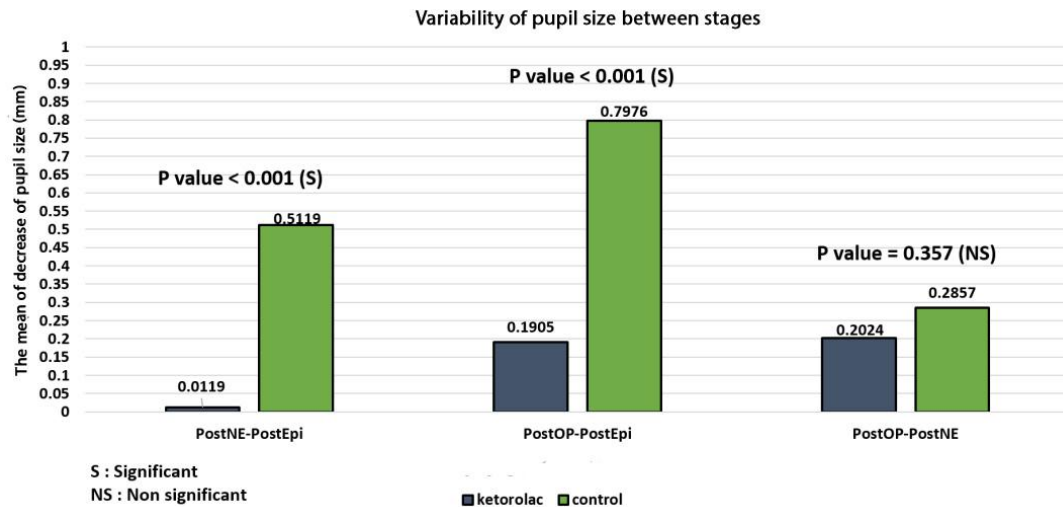
Characteristics	Ketorolac Group	Control Group	p-value
NS+4	16	16	0.47
psc+4/NS+2	2	1	0.44
psc+4/NS+3	0	2	0.74
psc+4/NS+4	0	1	0.88
psc+2/NS+2	1	0	0.82
cortical+3/NS+4	1	0	0.92
cortical+4/NS+2	0	1	0.99
Dense	1	0	0.74

**Table3- The comparison of pupil size at different stage between two groups**

Characteristics	Ketorolac Group	Control Group	p-value
Preoperative	6.26±0.62	6.23±0.87	0.92
After intracameral epinephrine injection	8.20±0.69	8.14±0.97	0.82
After nuclear emulsification	8.21±0.79	7.63±0.97	0.04
At the end of operation	8.01±0.67	7.34±1.04	0.01

**Figure 1- The comparison of pupil size at different stage between two groups**



**Figure 2- The comparison of the difference in mean pupil size at different stages between two groups**

## Discussion

This study showed that topical ketorolac is an effective inhibitor of miosis during phacoemulsification cataract surgery, and provides a more stable mydriatic effect throughout the surgical procedure. In the control group, a gradual failure in maintaining mydriasis was identified during the cataract extraction surgery in this study. Prevention of miosis during cataract surgery provides an adequate operative field and is a concern for many ophthalmologists. Traditionally, administration of topical agents such as phenylephrine, tropicamide, and cyclopentolate has been shown to improve maintaining mydriasis during surgery [11]. Ocular trauma secondary to cataract surgery plays an important role in secretion of PGs and causing pain, inflammation, increased IOP and trans-operative miosis [12]. Ketorolac is a NSAID product and inhibit COX-1 and COX-2 enzymes and thus, an inhibitor of PG synthesis [13-14]. Previous studies showed that NSAIDs are effective for prevention of trans-operative miosis [15-16].

In a recent study it was shown that use of ketorolac, prednisolone, or nepafenac was superior to placebo in maintaining intraoperative mydriasis [17]. Also, it was identified that preoperative administration of ketorolac for 3 days was more effective than use of one day preoperatively [8]. One study concluded that administration of intracameral agents such as lidocaine with or without epinephrine or phenylephrine was another approach commonly used in maintaining mydriasis during cataract extraction surgery [18]. Another study identified that use of lidocaine 1.0% alone resulted in significantly greater mean pupil diameters compared to topical mydriatics (cyclopentolate 1.0% and phenylephrine 5.0%) [19]. It was identified that Beehler pupil dilator and Malyugin ring are used for situations involving small pupils intraoperatively, however, use of these devices are accompanied with trauma of the iris and prolong the procedure and increase the postoperative inflammation [20].

Another complication after cataract surgery is pain after phacoemulsification technique. Previous study showed that moderate or severe pain after cataract surgery was indeed relatively common and 27% of patients experience this pain within 4 hours after procedure [21]. It was shown that use of

ketorolac before cataract surgery or during surgery could reduce the postoperative pain [12]. Combination of phenylephrine and ketorolac (Omidria) approved by FDA is a new treatment for this complication [22]. Ketorolac inhibits both COX-1 and COX-2 and by inhibition of synthesis of prostaglandins decreases the postoperative pain [23]. Also, ketorolac by inhibition of prostaglandin synthesis prevents surgically induced miosis. Combination of phenylephrine and ketorolac as a treatment option during cataract surgery with notable concerns about enhancing intraoperative mydriasis and reducing postoperative pain present a standard agent for this procedure. Furthermore, phenylephrine-ketorolac was not associated with any toxicity compared to placebo [23-26]. In the study of Hovanesian et al. 72% of patients were octogenarian and because many elderly patients have associated comorbidities, this study evaluated the safety and efficacy of combination of phenylephrine-ketorolac and supported the administration of this agent in elderly patients [12]. We concluded that topical ketorolac is an effective inhibitor of miosis during phacoemulsification cataract surgery, and provides a more stable mydriatic effect throughout the surgical procedure.

## References

- Uhr BW. History of ophthalmology at Baylor University Medical Center. *Proc (Bayl Univ Med Cent)*. 2003; 16(4): 435-8.
- Brian G, Taylor H. Cataract blindness--challenges for the 21st century. *Bull World Health Organ*. 2001; 79(3):249-56.
- Linebarger EJ, Hardten DR, Shah GK, Lindstrom RL. Phacoemulsification and modern cataract surgery. *Surv Ophthalmol*. 1999; 44(2):123-47.
- Camras CB, Miranda OC. The putative role of prostaglandins in surgical miosis. *Prog Clin Biol Res*. 1989; 312:197-210.
- Podos SM. Prostaglandins, nonsteroidal anti-inflammatory agents and eye disease. *Trans Am Ophthalmol Soc*. 1976; 74:637-60.
- Neal MJ. *Medical Pharmacology at a Glance*. 4th ed. Oxford: Blackwell Science; 2002.
- Yospaiboon Y, Luanratanakorn P, Noppawinyoowong C. Randomized double blind study of phenylephrine 2.5% vs 10% on pupillary dilation. *J Med Assoc Thai*. 2004; 87(11):1380-4.
- Stavert B, McGuinness MB, Harper CA, Guymer RH, Finger RP. Cardiovascular adverse effects of phenylephrine eyedrops: a systematic review and meta-analysis. *JAMA Ophthalmol*. 2015; 133(6):647-52.
- Narváez J, Kronberg BP, Park H, Zumwalt JR, Wong B, Bacon G, et al. Pupil dilation using a standard cataract surgery regimen alone

- or with atropine 1.0% pretreatment: prospective comparative evaluation. *J Cataract Refract Surg.* 2010; 36(4): 563-7.
10. Flach AJ, Dolan BJ, Donahue ME, Faktorovich EG, Gonzalez GA. Comparative effects of ketorolac 0.5% or diclofenac 0.1% ophthalmic solutions on inflammation after cataract surgery. *Ophthalmology.* 1998; 105(9):1775-9.
  11. Grob SR, Gonzalez-Gonzalez LA, Daly MK. Management of mydriasis and pain in cataract and intraocular lens surgery: review of current medications and future directions. *Clin Ophthalmol* 2014; 8:1281-9.
  12. Hovanesian JA, Sheppard JD, Trattler WB, Gayton JL, Malhotra RP, Schaaf DT, et al. Intracameral phenylephrine and ketorolac during cataract surgery to maintain intraoperative mydriasis and reduce postoperative ocular pain: Integrated results from 2 pivotal phase 3 studies. *J Cataract Refract Surg.* 2015; 41(10):2060-8.
  13. Ke TL, Graff G, Spellman JM, Yanni JM. Nepafenac, a unique nonsteroidal prodrug with potential utility in the treatment of trauma-induced ocular inflammation: II. In vitro bioactivation and permeation of external ocular barriers. *Inflammation.* 2000; 24(4):371-84.
  14. Lindstrom R, Kim T. Ocular permeation and inhibition of retinal inflammation: an examination of data and expert opinion on the clinical utility of nepafenac. *Curr Med Res Opin.* 2006; 22(2):397-404.
  15. Solomon KD, Turkalj JW, Whiteside SB, Stewart JA, Apple DJ. Topical 0.5% ketorolac vs 0.03% flurbiprofen for inhibition of miosis during cataract surgery. *Arch Ophthalmol.* 1997; 115(9):1119-22.
  16. Shaikh MY, Mars JS, Heaven CJ. Prednisolone and flurbiprofen drops to maintain mydriasis during phacoemulsification cataract surgery. *J Cataract Refract Surg.* 2003; 29(12):2372-7.
  17. Zanetti FR, Fulco EA, Chaves FR, da Costa Pinto AP, Arieta CE, Lira RP. Effect of preoperative use of topical prednisolone acetate, ketorolac tromethamine, nepafenac and placebo, on the maintenance of intraoperative mydriasis during cataract surgery: a randomized trial. *Indian J Ophthalmol* 2012; 60(4):277-81.
  18. Nikeghbali A, Falavarjani KG, Kheirkhah A, Bakhtiari P, Kashkoubi MB. Pupil dilation with intracameral lidocaine during phacoemulsification. *J Cataract Refract Surg* 2007; 33(1):101-3.
  19. Myers WG, Shugar JK. Optimizing the intracameral dilation regimen for cataract surgery: prospective randomized comparison of 2 solutions. *J Cataract Refract Surg.* 2009; 35(2):273-6.
  20. Akman A, Yilmaz G, Oto S, Akova YA. Comparison of various pupil dilation methods for phacoemulsification in eyes with a small pupil secondary to pseudoexfoliation. *Ophthalmology.* 2004; 111:1693-8.
  21. Porela-Tiihonen S, Kaamiranta K, Kokki M, Purhonen S, Kokki H. A prospective study on postoperative pain after cataract surgery. *Clin Ophthalmol.* 2013; 7:1429-35.
  22. Narvaez J, Kronberg BP, Park H, Zumwalt JR, Wong B, Bacon G, et al. Pupil dilation using a standard cataract surgery regimen alone or with atropine 1.0% pretreatment; prospective comparative evaluation. *J Cataract Refract Surg.* 2010; 36(4):563-7.
  23. Arshinoff SA, Opalinski YA. The pharmacotherapy of cataract surgery. In: Yanoff M, Duker JS, eds, *Ophthalmology*, 3rd ed. Philadelphia, PA, Mosby Elsevier, 2009; 434-440.
  24. Joshi RS. Pre-operative use of the topical steroidal and non-steroidal anti-inflammatory agents to maintain intra-operative mydriasis during cataract surgery. *Indian J Ophthalmol.* 2013 May; 61(5):246-7.
  25. Grob SR, Gonzalez-Gonzalez LA, Daly MK. Management of mydriasis and pain in cataract and intraocular lens surgery: review of current medications and future directions. *Clin Ophthalmol.* 2014; 8:1281-9.
  26. Lawuyi LE, Gurbaxani A. The clinical utility of new combination phenylephrine/ketorolac injection in cataract surgery. *Clin Ophthalmol.* 2015; 9:1249-54.