

"Shoulder Anterior Capsular Block: An Effective Strategy for Alleviating Pain During Shoulder Mobilisation in Adhesive Capsulitis Patients": A Case Series

Saravanakumar Sundaresan¹, Bhavani Vaidyanathan^{2*}, I. Joseph Raajesh²

¹Department of Anesthesiology, Government Tiruvallur Medical College and Hospital, Tiruvallur, India.

²Department of Anaesthesiology, Indiragandhi Medical College & Research Institute, Puducherry, India.

ARTICLE INFO

Article history:

Received 26 December 2023

Revised 16 January 2024

Accepted 29 January 2024

Keywords:

Suprascapular nerve;

Anterior approach axillary nerve;

Ultrasound;

Adhesive capsulitis;

Pericapsular

ABSTRACT

Frozen shoulder is a condition of varying severity characterized by the gradual development of global limitation of active and passive shoulder motion where radiographic findings are limited and associated with severe shoulder pain. Frozen shoulder is also referred to as adhesive capsulitis, painful stiff shoulder, and periarthritis. Treatment typically focuses on reducing shoulder pain and restoring joint mobilisation.

In the context of shoulder mobilization, the predominant nerve blocks encompass the interscalene, supraclavicular upper trunk block collectively referred to as the SCUT block, as well as the axillary nerve block. These nerve blocks demonstrate high efficacy in delivering targeted analgesia. However, a notable limitation of these interventions is the concomitant motor blockade and phrenic nerve block induced by them. This motor blockade poses a significant impediment to the initiation of early rehabilitation, thereby delaying the commencement of rehabilitative exercises and intervention.

Shoulder Anterior Capsular Block is a motor sparing block which can be effectively used in shoulder mobilisation.

Introduction

The prevalence of frozen shoulder is estimated to be 2 to 5 percent of the general population with female preponderance [1-3]. The exact cause of adhesive capsulitis is not well understood, but it can be associated with periods of immobilization, following surgery or an arm fracture. Certain groups are more at risk, including people over the age of 40 and women. People with certain medical conditions like diabetics and thyroid disorders are more prone for developing adhesive capsulitis [4-5].

The pathophysiology involves inflammation of the anterosuperior joint capsule, the coracohumeral ligament,

and the rotator cuff interval, followed by the development of adhesions and fibrosis of the synovial lining [6].

Innervation of shoulder joint is complex with 70 % contribution from suprascapular nerve, remaining from axillary, lateral pectoral, subscapular and musculocutaneous nerve.

Here we present a case series five patients with adhesive capsulitis who were given Shoulder anterior capsular Block (SHAC) block which is a motor sparing block and it blocks all the nerves supplying shoulder consistently.

Case Report

Case 1

The authors declare no conflicts of interest.

*Corresponding author.

E-mail address: bhavanivaidyanathan@gmail.com

Copyright © 2024 Tehran University of Medical Sciences. Published by Tehran University of Medical Sciences.



This work is licensed under a Creative Commons Attribution-NonCommercial 4.0 International license (<https://creativecommons.org/licenses/by-nc/4.0/>). Noncommercial uses of the work are permitted, provided the original work is properly cited.

51-year-old male patient with no comorbidities complained of chronic, severe, nagging pain deep in the shoulder left joint especially at night, and of progressive global stiffness of the shoulder that severely restricts activities of daily living. Clinical examination showed decreased range of shoulder movements especially abduction and external rotation. Xray shoulder joint appeared normal. Patient was treated with T. Ibuprofen twice daily for 3 months.

Case 2

61-year-old female, diabetic on oral hypoglycaemic agents complains of progressive nocturnal pain in right shoulder for 6 months for which she was treated with oral anti inflammatory medications and physical therapy and transdermal diclofenac patch. She had difficulty in reaching out to things overhead and progressive stiffening of shoulder. Xray shoulder was unremarkable.

Case 3

54-year-old female obese diabetic suffered from pain in the right shoulder, which significantly limited his routine activities and forced him to take analgesics daily. He exhausted almost all conservative measures and had difficulty reaching his back.

Case 4

A 61-year-old female patient high BMI and short neck had pain in right shoulder and difficulty in external rotation and abduction following a trauma to distal humerus. Her upper arm was immobilised for 3 months. She was not responding to pharmacological treatment.

Case 5

A 65-year-old lady with multiple comorbidities hypothyroid hypertension, and diabetes mellitus with shoulder pain following history of fall. Physical examination revealed generalized shoulder tenderness with grossly limited range of movements. Conservative treatments like hot packs, oral paracetamol and NSAIDS didn't relieve her pain.

All five patients had a painful stiff shoulder inability to use the affected arm for daily activities with normal laboratory values for erythrocyte sedimentation rate, rheumatoid factor, C-reactive protein, thyroid hormone assay. Xray of the affected shoulder joint was normal. MRI of the shoulder was not taken in these patients. (Table 1)

Table 1- Demographic profile and pain scores of the patients

Patient	Age	Gender	Before block	Post block	NRS		
					1week	1month	3 month
1	51	M	8/10	2/10	3/10	2/10	3/10
2	61	F	8/10	0/10	3/10	1/10	2/10
3	54	F	7/10	2/10	2/10	2/10	3/10
4	61	F	9/10	3/10	2/10	3/10	2/10
5	65	F	8/10	1/10	1/10	2/10	2/10

Procedure

All the patients were placed in supine position with the arm extended and abducted. High frequency linear probe (Sono site M turbo) was placed transversely with medial end resting on coracoid and lateral end at the humerus. The shoulder anterior capsular block (SHAC) targets an interfascial and pericapsular space (Figure 1A-D). Following sterile skin preparation, SHAC block was performed under ultrasound guidance by visualization of the interfascial space between the deep lamina of the deltoid muscle fascia and the superficial lamina of the subscapularis fascia and glenohumeral pericapsular space. A 20-gauge venflon stylet was used for injection and in plane needling was done from lateral to medial side. Hydro dissection of interfascial plane was done with of 5% Dextrose and subsequently 10 ml of 0.25 % bupivacaine was injected in the interfascial plane. Second injection was injected deep to subscapularis muscle in pericapsular space. 10 ml 0.25 % bupivacaine was injected in pericapsular space. Fifteen minutes after the block NRS was noted [7]. Shoulder mobilisation was done by an orthopaedician when pain scores were less than two. Pain during the mobilisation was noted.

Shoulder rest combined with gentle range of motion exercises for the glenohumeral joint was advised for initial days. At the end of first week after initial review physical therapy with active glenohumeral mobilisation was performed in all patients only if they do not cause undue discomfort.

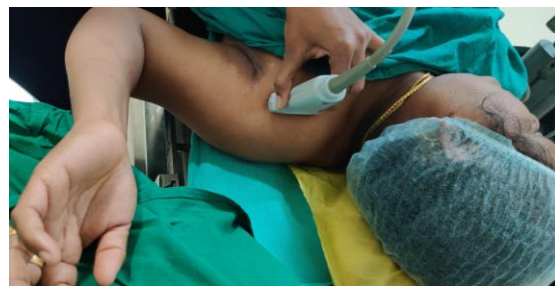


Figure 1A- Probe position

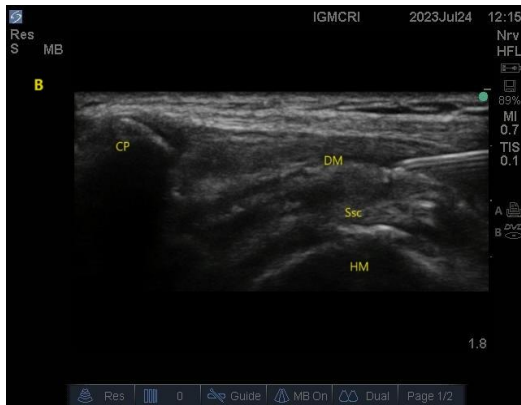

Figure 1B- Sonoanatomy of SHAC block

CP-Coracoid process, DM-Deltoid muscle, Ssc-Subscapularis, HM -Humerus

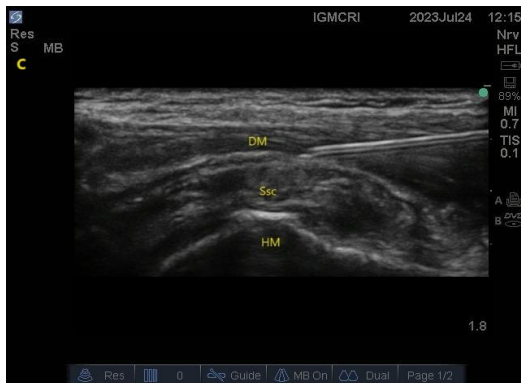

Figure 1C-Interfascial injection

DM-Deltoid muscle, Ssc-subscapularis muscle, HM-Humerus

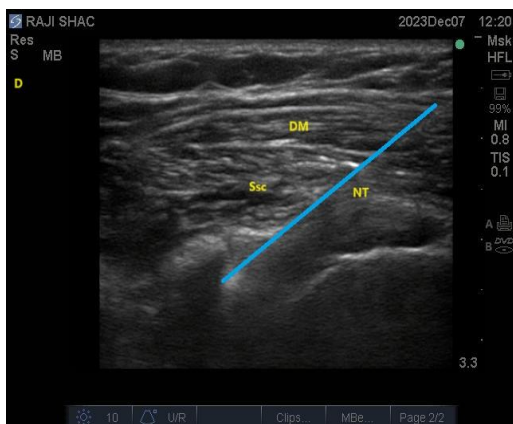


Figure 1D-Pericapsular injection

DM-Deltoid muscle, Ssc-Subscapularis muscle, Blue line NT needle trajectory

Discussion

Ultrasound-guided regional anaesthesia (USRA) has gained widespread acceptance in both surgical anaesthesia and pain management domains. Most commonly used blocks for shoulder procedures include ultrasound guided interscalene and supraclavicular upper trunk block which causes phrenic nerve blockade and motor weakness, hindering early mobilisation in adhesive capsulitis.

The suprascapular nerve innervates 70% of the shoulder area, including the superior and posterior regions of the shoulder joint, the capsule and the acromioclavicular joint [8].

The axillary nerve supplies the humeral portion of anterior and anteroinferior capsule. Lateral pectoral nerve innervates the anterosuperior capsule of the shoulder [9-10].

Ultrasound guided suprascapular and axillary nerve block is yet another adjunct block employed in adhesive capsulitis for shoulder mobilisation. Blocking the axillary nerve posteriorly at the quadrangular space will not block the articular branches to the shoulder joint which are given earlier, resulting in incomplete analgesia [11]. Moreover, suprascapular and axillary nerve block will not cover the other nerves supplying shoulder such as lateral pectoral, musculocutaneous and subscapular nerve which are effectively blocked by SHAC block [12].

SHAC block targets the nerves supplying the shoulder at two places. The first block given in the interfascial space between the deep layer of the deltoid fascia and the superficial layer of the subscapularis fascia, anterior to the subscapularis myotendinous junction. Injectate given here blocks, the axillary nerve and the subscapular nerves, the lateral pectoral nerve, and the musculocutaneous nerve. Second injection given in the pericapsular space, deep to subscapularis tendon will block the terminal articular branches indistinctly from their origin [11].

We had difficulty in positioning the arm in abduction and external rotation in two of our patients because of pain. All our patients had significant reduction in pain score fifteen minutes after block.

Limitations of the study

We assessed only improvement in pain using numeric rating scale but multidimensional assessment score like the Shoulder Pain and Disability Index (SPDI) would have been better index to assess the quality of the life of the patients and we didn't measure the improvement in range of movement and results would have been better if musculoskeletal ultrasound of shoulder has been incorporated in our study. Longer follow up would have been better to know the long-term benefits of the block.

Conclusion

In conclusion, our case series demonstrates that patients with adhesive capsulitis of the shoulder experienced a significant reduction in pain scores following the SHAC block. This intervention facilitated nearly painless mobilization, allowing the orthopedic team to achieve full shoulder movement, including abduction and external rotation. The SHAC block, characterized by its motor and diaphragm sparing properties, plays a crucial role in early rehabilitation for adhesive capsulitis. Its efficacy is underlined by its consistent blockade of all nerves supplying the shoulder joint, thereby providing substantial therapeutic benefits in the management of this condition.

References

- [1] Wilson AT, Nicholson E, Burton L, Wild C. Analgesia for day-case shoulder surgery. *Br J Anaesth.* 2004; 92(3):414-5.
- [2] Zreik NH, Malik RA, Charalambous CP. Adhesive capsulitis of the shoulder and diabetes: a meta-analysis of prevalence. *Muscles Ligaments Tendons J.* 2016; 6(1):26-34.
- [3] Walker-Bone K, Palmer KT, Reading I, Coggon D, Cooper C. Prevalence and impact of musculoskeletal disorders of the upper limb in the general population. *Arthritis Rheum.* 2004; 51:642.
- [4] Dyer BP, Rathod-Mistry T, Burton C, et al. Diabetes as a risk factor for the onset of frozen shoulder: a systematic review and meta-analysis. *BMJ Open.* 2023; 13:062377.
- [5] Bowman CA, Jeffcoate WJ, Patrick M, Doherty M. Bilateral adhesive capsulitis, oligoarthritis and proximal myopathy as presentation of hypothyroidism. *Br J Rheumatol.* 1988; 27:62.
- [6] Lee JC, Guy S, Connell D, Saifuddin A, Lambert S. MRI of the rotator interval of the shoulder. *Clin Radiol.* 2007; 62(5):416-23.
- [7] Galluccio F, Fajardo Perez M, Yamak Altinpulluk E, Hou JD, Lin JA. Evaluation of Interfascial Plane and Pericapsular Nerve Blocks to the Shoulder Joint: A Preliminary Analysis of Shoulder Anterior Capsular Block. *Pain Ther.* 2021; 10(2):1741-1754.
- [8] Verma D K, Neyaz O, Nanda S, Handa G. Comparison of Outcome of Ultrasound-Guided Suprascapular Nerve Block versus Intra-articular Steroid Injection in Adhesive Capsulitis of Shoulder: A Randomized Control Trial. *Indian Journal of Rheumatology.* 2019; 14(2): 113-118.
- [9] Laumonerie P, Dalmas Y, Tibbo ME, Robert S, Faruch M, Chaynes P, et al. Sensory innervation of the human shoulder joint: the three bridges to break. *J Shoulder Elbow Surg.* 2020; 29(12):e499-e507.
- [10] Eckmann MS, Bickelhaupt B, Fehel J, Benfield JA, Curley J, Rahimi O, et al. Cadaveric Study of the Articular Branches of the Shoulder Joint. *Reg Anesth Pain Med.* 2017; 42:564–70.
- [11] Ramadurai R, Bhoi D, Nagarajappa A, Amar P. Pericapsular nerve group block (PENG) at neutral position for shoulder manipulation: A feasible approach for a new indication. *J Clin Anesth.* 2021; 75:110541.
- [12] Yamak Altinpulluk E, Teles AS, Galluccio F, Simón DG, Olea MS, Salazar C, et al. Pericapsular nerve group block for postoperative shoulder pain: A cadaveric radiological evaluation. *J Clin Anesth.* 2020; 67:110058.