

# Intraoperative Difficult Airway Management in Patient with Pan Facial Fracture Using Airway Manoeuvre Involving Fiberoptic Intubation and Submental Intubation

Sumedha Mehta\*, Girish Saundattikar, Kiran.C.Valake, Swapnil.G.Kandukwar

Department of Anaesthesiology, SKNMC & GH, Pune, India.

## ARTICLE INFO

### Article history:

Received 18 March 2024

Revised 11 April 2024

Accepted 26 April 2024

### Keywords:

Submental intubation;

Awake fiberoptic;

Panfacial fracture

## ABSTRACT

Intraoperative Airway management of Pan facial fracture is always challenging due to difficult airway resulting from airway trauma and airway sharing between the anesthesiologist and maxillofacial surgeon. Submental intubation is considered a good alternative technique over tracheostomy for providing a clear field intraoperatively for maxillofacial fracture fixation. We want to discuss airway management maneuvers using Awake fiberoptic bronchoscope-assisted intubation and submental intubation technique and the challenges we faced in a patient presented with Pan- facial fracture with difficult airway posted for surgery.

## Introduction

Airway management of Pan facial fracture presents with its own set of challenges due to the complexity of the fracture, difficult airway, and sharing of airway between the anaesthesiologist and maxillofacial surgeon. The most common factor related to mortality in trauma patients is critical care errors in airway and respiratory management like failure to intubate, secure, or protect the airway [1]. We want to discuss our airway management manoeuvres using Awake fiberoptic bronchoscope-assisted intubation and submental technique and the challenges we faced in a patient presented with Pan facial fracture with difficult airway posted for surgery.

## Case Report

We report a case of 30 years old male patient, weighing 70 kg, with history of road traffic accident presented with history of oral and nasal bleeding, Pan facial fractures with depressed upper dental line and right clavicle displaced fracture with no cervical involvement. Patient

had primary treatment in another hospital and was then referred to our Institution for further surgical management. After detailed assessment, the patient was posted for Open Reduction and Internal fixation (ORIF) of Mandible, Maxilla and Clavicle fractures.

A detailed Pre-anesthetic evaluation of the patient including clinical examination and investigations was done. Patient was vitally stable with no known comorbidities. On Airway examination mouth opening was restricted due to fracture and pain, MPC could not be assessed. Multiple loose teeth and missing molars were seen.

On Investigation, CT scan Brain and 3D CT Face (Figure 1a) showed Comminuted and displaced fractures of Bilateral orbit with pneumo-orbit, Bilateral nasal bone, nasal septum, cribriform plate, bilateral maxillary sinus with hemosinus, bilateral medial and lateral pterygoid plates, linear displaced fracture of zygomatic arch, mandible & comminuted fracture of alveolar process of maxilla extending to hard palate with normal brain parenchyma.

X-ray chest (Figure 1b) was normal and showed Right clavicle displaced fracture. All laboratory examinations were within normal limits. Neurosurgical opinion was done, and no active management was advised. Patient

The authors declare no conflicts of interest.

\*Corresponding author.

E-mail address: [drsumedhamehta1@gmail.com](mailto:drsumedhamehta1@gmail.com)

Copyright © 2025 Tehran University of Medical Sciences. Published by Tehran University of Medical Sciences.



This work is licensed under a Creative Commons Attribution-NonCommercial 4.0 International license (<https://creativecommons.org/licenses/by-nc/4.0/>). Noncommercial uses of the work are permitted, provided the original work is properly cited.

was posted for ORIF of Pan Facial Fracture and Right Displaced Clavicle Fracture under General Anesthesia.

After a detailed discussion with the Maxillofacial surgeon and understanding the plan of surgery, we decided on Awake oral fiberoptic intubation for first securing the airway and then we planned for submental intubation as oral intubation would hinder surgery and then again, the oral placement of Endotracheal tube after completion of surgery for elective postoperative ventilation.

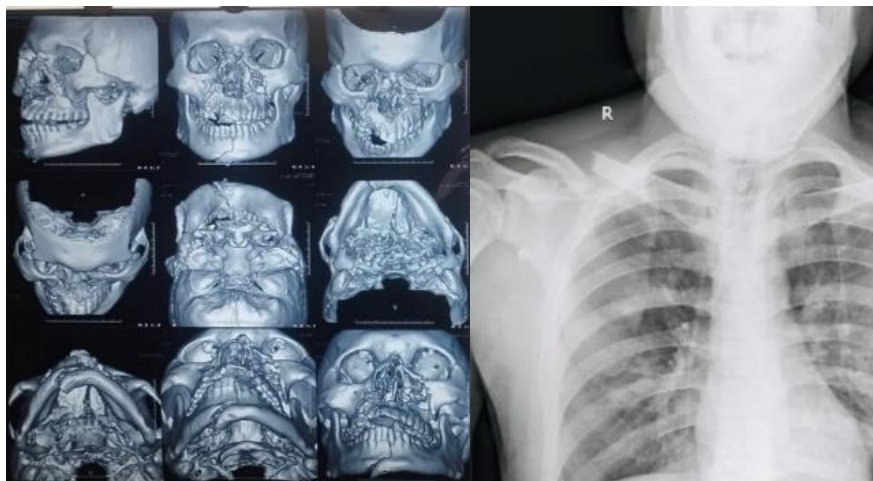
Our plan of anesthesia was first to secure the airway safely with Awake oral fiber optic intubation with preparation of Emergency Tracheostomy if required. The plan of anesthesia was discussed with the patient and counseling was done for Awake Fiberoptic Bronchoscopy. Operating room was prepared with Difficult Airway Cart with fiberoptic bronchoscope, appropriate size flexometallic tube, drugs as per body weight, and warming equipment.

After confirming nil by oral status and taking written informed consent, patient was shifted to OT. All standard ASA monitors like electrocardiography, pulse oximeter, non-invasive blood pressure, capnography, and temperature probe were connected. Wide bore 18 G Intravenous access was secured, and Ringer Lactate started. Airway preparation was done with 4% lignocaine nebulization, airway blocks with 2% Lignocaine and 10% Lignocaine spray. Patient was pre-medicated with Inj. Glycopyrrolate 0.2mg iv, Inj. Midazolam 1mg iv, Inj. Ondansetron 4mg iv. Sedation was maintained with Inj Dexmedetomidine 50 mcg iv bolus and Inj Fentanyl 50 mcg iv in graded doses. Oxygen supplementation was provided throughout the procedure. Fiberoptic bronchoscope guided awake oral intubation done with Flexometallic tube (FMT) no 7.5 after confirming bilateral air entry and capnograph, FMT tube was secured. Induction done with Inj Propofol 120mg iv and Inj Vecuronium 5mg iv and anaesthesia was maintained

on O<sub>2</sub>, Air (50:50) and Sevoflurane (1%–2%) on Volume AC mode. Clavicle fracture was first operated and ORIF with plating of Right clavical done by Orthopaedic surgeon.

After that preparation for submental intubation (Figure 2a) was done for ORIF with plating of maxilla, mandible along with nasal bone reduction (Figure 2b). The maxillofacial surgeon performed the procedure by taking submental incision just medial to the lower border of the mandible. The subcutaneous tissues and the tissues of the floor of the mouth were bluntly dissected with Kelly forceps to the point of entering the oral cavity. Care was taken to avoid nerves, vessels, and salivary structures. The endotracheal tube was then disconnected from the ventilatory circuit and connector of FMT removed and was pulled through the submental tunnel, along with the pilot balloon, using the forceps. We faced one problem during submental intubation the pilot balloon tube got stuck and after some manipulation it passed through submental tunnel. The circuit was then quickly reconnected, and tube positioning was confirmed by bilateral breath sounds, ETco<sub>2</sub> and then, FMT was secured.

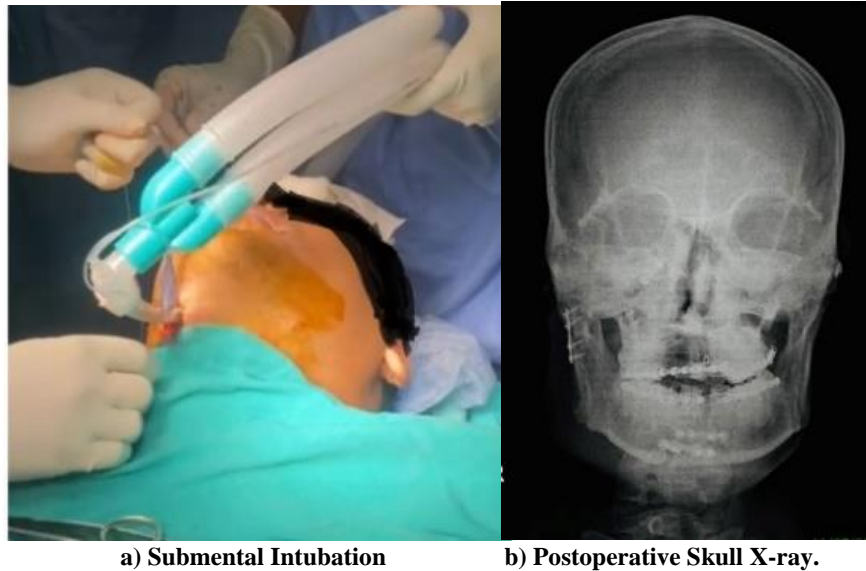
Intraoperative Analgesia was maintained with intravenous Inj dexmedetomidine (0.3-0.6mcg), Inj Fentanyl (1mcg/kg), and Inj Paracetamol 15mg/kg. All vital parameters including EtCo<sub>2</sub>, and airway pressures were monitored throughout the surgery. Surgery went uneventful, blood loss was calculated and replaced accordingly. At the end of the surgery, the tube was disconnected, pulled back into the oral cavity and reconnected. The submental incision was sutured, Flexometallic ETT exchanged with Portex cuffed ETT no. 7.0. Patient was shifted with ETT in situ for elective ventilation to Intensive Care Unit as per our Institutional protocol. After 12 hours the patient was extubated uneventfully and recovered well postoperatively.



a) 3D-CT of Face

b) X-ray-Rt Clavicle fracture

**Figure1- Preoperative Investigations**



**Figure 2- a) Intraoperative Submental intubation b) Postoperative Skull X-ray**

## Discussion

Maxillofacial injuries especially Pan facial fractures require specialized management due to the airway involvement and complexity of the fracture. This type of fractures requires detailed planning and precise execution in Airway management from both Maxillofacial Surgeon and Anaesthesiologist. In cases of pan-facial fracture, maxillomandibular fixation is surgical necessity to do accurate plating of various mandibular and maxillary fractures, so nasal intubation is preferred over oral intubation. Intraoperative airway management of patients with pan facial fracture have been described using different techniques including nasal intubation under direct vision, blind nasal intubation, fiberoptic guided nasal intubation, retromolar intubation, submental intubation, and tracheostomy [2]. When nasal fractures are involved submental intubation or tracheostomy are considered as alternate options for securing the airway.

Submental intubation has been frequently used and preferred method of airway control over tracheostomy in maxillofacial surgery since its first description by Francisco Hernández Altemir in 1986 [3]. Submental intubation provides a secure airway and does not interfere with maxillomandibular fixation facilitating better visualization and manipulation during the procedure with minimal complication rate [4].

In our case, we faced multiple challenges like difficult mask ventilation and difficult airway due to presence of displaced nasal bone fracture, limited mouth opening and pan facial fractures. Awake fiberoptic intubation is considered as gold standard technique in management of Difficult Airways. We planned Awake oral fiberoptic intubation for first securing the airway considering the safety of patient. We preferred oral route and avoided

nasal intubation due to chances of bleeding and dislodgement of bone fragments during nasal intubation. Nasotracheal intubation is not recommended in the presence of pan-facial fracture, cranial base fracture with or without CSF rhinorrhoea, bleeding disorder, distorted nasal anatomy, and when nasal packing is indicated. It may lead to epistaxis, sinusitis, meningitis, sepsis, injury to the adenoids, dislodgment of bony fragments and rarely intracranial intubation [5-6]. However, Oral awake fiberoptic intubation in our patient was also challenging due to pain, limited mouth opening and the presence of displaced fractures. Skilful and smooth fiberoptic intubation was done in our case as any bleeding during the procedure would have hampered the vision for fiberoptic intubation. We consider good patient counselling, 10% Lignocaine spray, and adequate sedation provided by Inj dexmedetomidine and Inj fentanyl as important factors for successful awake fiberoptic bronchoscopy.

Submental intubation is preferred over tracheostomy as it avoids complications associated with tracheostomy, such as haemorrhage, emphysema, tube blockage, tracheal stenosis, tracheomalacia and scarring [7]. Submental intubation technique has its own complications like soft tissue damage, blood clot inside Endotracheal tube, high airway pressure due to acute bend, Cuff of the tube can be damaged during manipulation, difficulty in removing connector of reinforced tube. However, these complication rates are found to be low, so this technique can be used safely in air management [8].

In an interesting case report by Jung I. et.al, submental intubation was done using laparoscopic trocar, through which sufficient space was created for the insertion of the endotracheal tube. They found that this novel approach

did not require any blunt dissection and caused significantly less soft tissue damage and required less time [9].

J.D. Green et al described a modified technique, also known as two tubes method. In this first orotracheal tube was conventionally placed, then second tube passed submentally and then first tube removed and replaced with submental tube. The advantage of this technique is that there is less risk of compromising the patient's airway if difficulties were encountered in re-attaching the connector or passing the tube through the incision. Also, there is no need to remove universal connector as the manufacturer's design of some reinforced specifically prevents the removal of the universal connector [10]. We faced an incident of the pilot balloon of FMT being stuck while passing the tube through submental tunnel which was resolved by little manipulation with no episode of hypoxia during this short apnea period.

Postoperatively, due to extensive surgery and manipulation, mucous membranes and soft tissues can become oedematous and swollen which may result in airway compression. In intubated maxillofacial trauma patients, extubation should be deferred until normal anatomy is restored or at least until the oedema subsides [11]. According to our institutional protocol after 12 hrs postoperatively, extubation was done with difficult airway cart ready, which underwent uneventfully, and patient was kept under vigilant monitoring. Our case was challenging as it posed numerous challenges as there were airway manoeuvres that required skills of both the anaesthesiologist and maxillofacial surgeon because of sharing the airway. We consider clear communications and good coordination between the Anaesthesiologist and Maxillofacial surgeon while manoeuvring the Endotracheal tube during submental intubation as a key aspect in successful management.

We want to share our experience with this novel technique of submental intubation which we consider safe in providing secure airway during surgery in patients with Pan facial fracture. Successful airway management of Pan facial fracture requires an understanding of the complexity of the fracture, detailed planning for safe submental intubation, experienced anaesthesiologists, and maxillofacial surgeons.

## Conclusion

Submental Intubation can be considered a safe alternative to Tracheostomy in airway management of patients with Pan facial Fracture.

## Acknowledgment

We acknowledge the inputs and cooperation from the Department of Oromaxillofacial Surgery, Sinhgad Dental College and Hospital, Pune.

## References

- [1] Garcia A. Critical care issues in the early management of severe trauma. *Surg Clin North Am.* 2006; 86(6):1359-87.
- [2] Kellman RM, Losquadro WD. Comprehensive airway management of patients with maxillofacial trauma. *Craniomaxillofac Trauma Reconstr.* 2008; 1(1):39-47.
- [3] Hernández AF. The submental route for endotracheal intubation. *A New Technique J Maxillofac Surg.* 1986; 14(1):64-5.
- [4] Das S, Das TP, Ghosh PS. Submental intubation: A journey over the last 25 years. *J Anaesthesiol Clin Pharmacol.* 2012; 28(3):291-303.
- [5] Hall CE, Shutt LE. Nasotracheal intubation for head and neck surgery. *Anaesthesia.* 2003; 58(3):249-56.
- [6] Arrowsmith JE, Robertshaw HJ, Boyd JD. Nasotracheal intubation in the presence of frontobasal skull fracture. *Can J Anaesth.* 1998; 45(1):71-5.
- [7] Mehta AK, Chamyal PC. Tracheostomy Complications and their Management. *Med J Armed Forces India.* 1999; 55(3):197-200.
- [8] De Toledo GL, Bueno SC, Mesquita RA, Amaral MB. Complications from submental endotracheal intubation: a prospective study and literature review. *Dent Traumatol.* 2013; 29(3):197-202.
- [9] Jung I, Yoo BH, Ju JY, Choi S, Yon JH, Kim KM, et al. Novel alternative for submental intubation - A case report. *Anesth Pain Med (Seoul).* 2020; 15(2):247-250.
- [10] Green JD, Moore UJ. A modification of sub-mental intubation. *Br J Anaesth.* 1996; 77(6):789-91.
- [11] Krausz AA, El-Naaj IA, Barak M. Maxillofacial trauma patient: coping with the difficult airway. *World Journal of Emergency Surgery: WJES.* 2009; 4:21.